

# Scrotal Scintigraphy in Testicular Torsion: An Experience at a Tertiary Care Centre

Saleh O, El-Sharkawi MS, Imran MB

Department of Radiology and Medical Imaging, King Khalid University Hospital and College Of Medicine, King Saud University, Riyadh, Saudi Arabia

## ABSTRACT

**Introduction:** Accurate diagnosis of testicular torsion is important to avoid serious consequences of any delay in proper management. Objective of this study was to compare performance parameters of scrotal scintigraphy and scrotal ultrasound to correctly and confidently diagnose the etiology of an acute scrotum in university hospital settings. **Materials and Methods:** This is an observational study with a retrospective analysis of data from July 2004 to March 2009. A total of 21 patients (age three years to 37 years) were referred from Emergency Department for scrotal scintigraphy to rule out testicular torsion. All patients went through a standard protocol for scrotal scintigraphy upon referral to Nuclear Medicine Department. Scrotal ultrasound was performed either before or immediately after the scintigraphy. **Results:** Confirmation of the diagnosis in all 21 patients was based either on the histopathological report of the surgical specimen (n=7) or through clinical follow up (for conservative treatment; n=14). At presentation, nine patients (43%) had left sided pain, and 12 patients (57%) had right sided pain ( $p>0.05$ ). Eight patients (38%) were diagnosed to have testicular torsion on scintigraphy; one of them turned out to be false positive (testicular abscess). Sensitivity of scrotal scintigraphy to diagnose testicular torsion was 100%, specificity 93%, negative predictive value (NPV) 100% and positive predictive value (PPV) 88%. **Conclusion:** Scrotal scintigraphy in an acute scrotum is a feasible procedure to be performed on emergency basis, and it is a valid and reliable test to diagnose testicular torsion when US is doubtful or non conclusive.

**KEYWORDS:** Scrotal, torsion, scintigraphy, epididymo-orchitis, ultrasound.

## INTRODUCTION

Acute scrotal pain is one of the commonest urological emergencies, which may have serious consequences. Children and adolescent may experience this vital condition.<sup>1</sup> Acute scrotum is a clinical presentation of many pathological conditions, including testicular torsion, epididymo-orchitis, trauma and hydrocele.<sup>2</sup> Testicular torsion is the most serious of them requiring prompt diagnosis and early surgical intervention to save the testis. Salvation of the testis is only possible in a short but crucial time window because after about 12-24 hours of torsion, the affected testis becomes non-viable.<sup>3,4,5</sup> Even after this complication, surgical intervention is deemed necessary for prophylactic fixation of the contralateral testis.

In a substantial number of cases, it is difficult to differentiate testicular torsion from non-torsion

conditions especially epididymo-orchitis merely based on clinical features. In one retrospective study analyzing 204 boys with acute scrotum, no significant difference was found in clinical features between testicular torsion and epididymo-orchitis.<sup>6</sup> Furthermore, if there is a history of trauma, then there is strong temptation to attribute the pain and other symptoms to preceding trauma.<sup>7</sup> A reliable test is therefore, necessary to investigate all cases of the acute scrotum to correctly establish the diagnosis.

Scrotal scintigraphy has been in routine use since 1971 and proved as a powerful diagnostic tool for scrotal emergencies. It has kept up its relevance until recent years where the diagnostic preference was challenged by scrotal ultrasound (US) with Doppler.<sup>8,9</sup> Greater anatomical details, wide availability and radiation free made the latter modality more popular.<sup>10</sup> However, US, as any other diagnostic tests may not answer the clinical question and fail to give a definite answer because of technical or expertise limitations requiring a confirmatory test. In this retrospective study, we have tried to sum-up our experience at a university hospital on the use of scrotal scintigraphy in the acute scrotum within that context.

## MATERIAL AND METHODS

This is a retrospective analysis of data from July 2004 to March 2009. A total of 21 patients was referred from Emergency Department for scrotal scintigraphy to rule out testicular torsion. Scrotal US and scrotal scintigraphy were performed in a random manner

Saleh Othman  
Associate Professor and Consultant  
Nuclear Medicine Division  
Department of Radiology and Medical Imaging  
King Khalid University Hospital and  
College Of Medicine  
King Saud University  
P.O. Box: 7805(46)  
Riyadh 11472 - Saudi Arabia  
Telephone No.: 00 966 1 4671159  
Fax No.: 00 966 1 4672675  
E-mail: sothman@ksu.edu.sa

(either was performed first). Final diagnosis was made either on the histopathological report of the surgical specimen (n=7) or through clinical follow up (if surgery was not performed; n=14). The age of the patient ranged from 3-37 years.

Scrotal scintigraphy was performed following a standard protocol of the department (policy and procedure of the university hospital). No patient preparation or sedation is required. Patient is rested in supine position on the imaging table. A dose of 5-10 mCi of technetium pertechnetate (Na-Tc<sup>99m</sup> O<sub>4</sub>) was administered intravenously as a rapid bolus. Images were obtained on imaging matrix of 128x128 with a dual head gamma camera (ADAC-FORTE) equipped with low energy parallel hole all purpose collimator (only anterior view for evaluation). Initial dynamic study of 16 frames of 4 seconds each (flow images) followed by a static image of 3-minute duration (tissue phase image) of the scrotal region, including the lower pelvis and upper thighs was obtained. The penis was taped to the lower abdominal wall. Shielding of bladder, penis and thighs

were done to acquire maximum counts from the area of interest. An additional image with a Co<sup>57</sup> marker in the midline of the scrotum (median raphe) was also obtained.

The criterion for acute torsion was, reduced or absent tracer concentration compared to contra-lateral testis. Missed torsion was diagnosed as a central photopenic area surrounded by rim of increased tracer distribution (ring sign or doughnut sign). Initial report was given immediately to the treating physician after concluding the study.

US was performed by the radiologist on call, with the patient in supine position. Gray scale images were acquired in transverse and longitudinal sections of both sides. Study was supplemented by the Doppler flow images. Torsion was diagnosed when blood flow to the symptomatic testis was absent or substantially reduced compared to the asymptomatic side.

**Table 1.** Demographic data showing the age, month of presentation (to see the impact of weather), side of testicular involvement and scintigraphic findings

S/No	Patient ID	Age(Yr)	Scan time	R/L	Scrotal scintigraphy Report
1	H	26	February 2004	Right	Space occupying lesion
2	B	14	July 2004	Right	Epididymo-orchitis
3	B	14	Sept2004	Right	Torsion ruled out/mass
4	Y	17	July 2005	Right	Epididymo-orchitis
5	A	34	July 2006	Right	Multicystic lesion
6	A	8	June 2006	Right	Normal
7	A	22	April 2006	Left	Epididymo-orchitis/ reversed torsion
8	N	17	March 2006	Left	Missed Torsion
9	K	3	July 2007	Right	Missed Torsion
10	M	12	May 2007	Left	Torsion
11	A	20	March 2008	Left	Torsion
12	Y	17	March 2008	Left	Normal
13	A	26	August 2008	Left	epididymoorchitis
14	A	37	January 2009	Right	epididymoorchitis
15	A	16	February 2009	Right	Torsion
16	I	17	February 2009	Left	Space occupying lesion
17	A	18	February 2009	Right	Missed Torsion
18	A	18	February 2009	Right	Missed Torsion
19	G	14	February 2009	Left	Missed Torsion
20	S	24	March 2009	Left	SOL
21	M	10	March 2009	Right	Normal

R/L, presentation laterality, right or left

Scan time: Month of Gregorian calendar when scrotal scintigraphy performed

RESULTS

Demographic data of all the patients included in this study (n=21) is shown in Table 1. Month of presentation and age distribution were considered at the time of result's analysis. At presentation, nine patients (43%) had left sided scrotal pain and 12 (57%) had right sided pain (p>0.05). Eight of the total patients (38%) were diagnosed as having torsion on scintigraphy, which was confirmed surgically in seven

patients and the eight patient turned out to be false positive during surgical intervention (testicular abscess). Figures 1 to 4 show scintigraphic patterns of various testicular disorders. Sensitivity of scrotal scintigraphy to diagnose testicular torsion was 100%, specificity 93%, negative predictive value (NPV) 100% and positive predictive value (PPV) 88%.

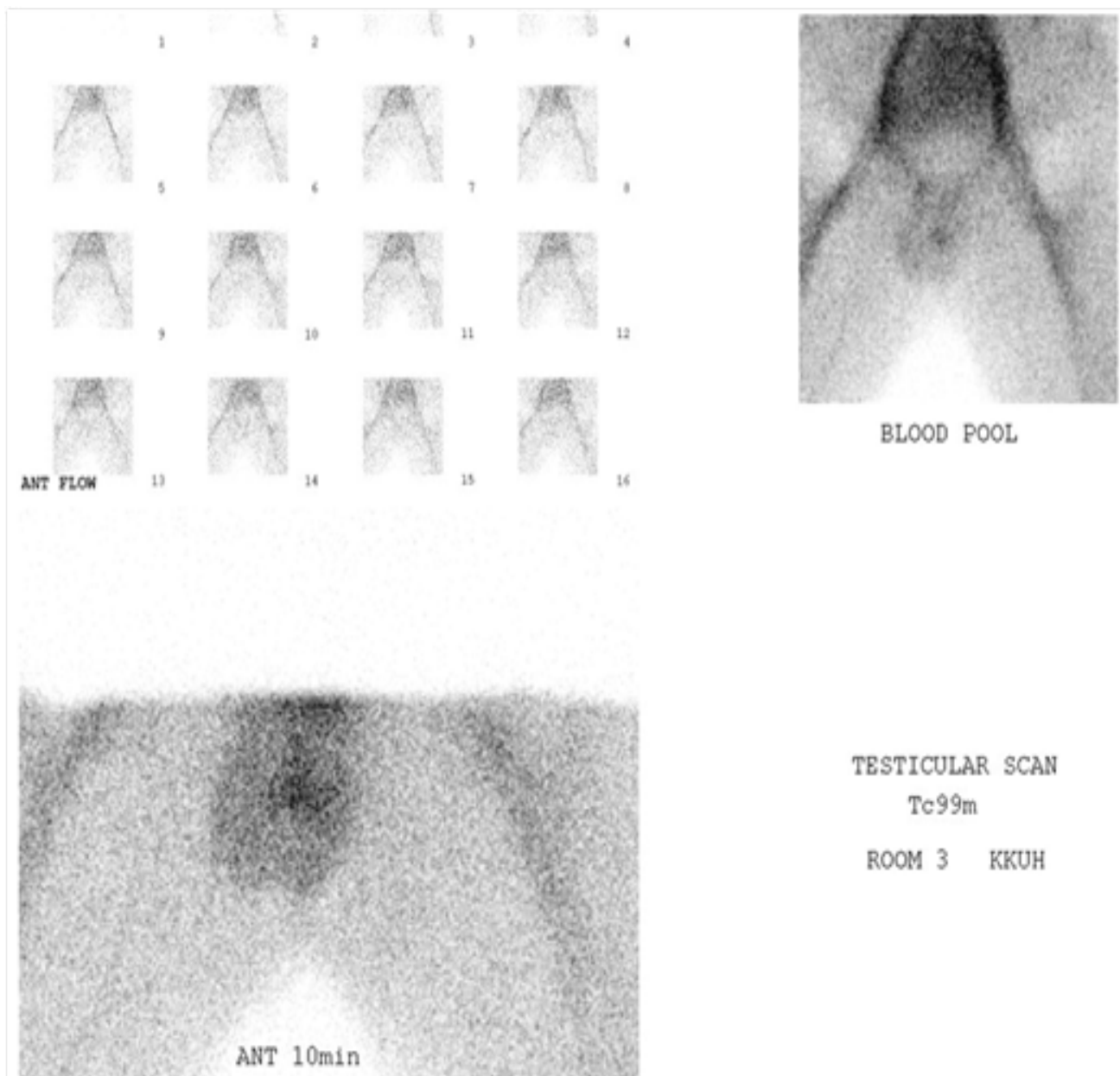


Figure 1. A 17 year old male patient who presented with left sided scrotal pain. However a normal scrotal scintigraphic pattern was demonstrated.

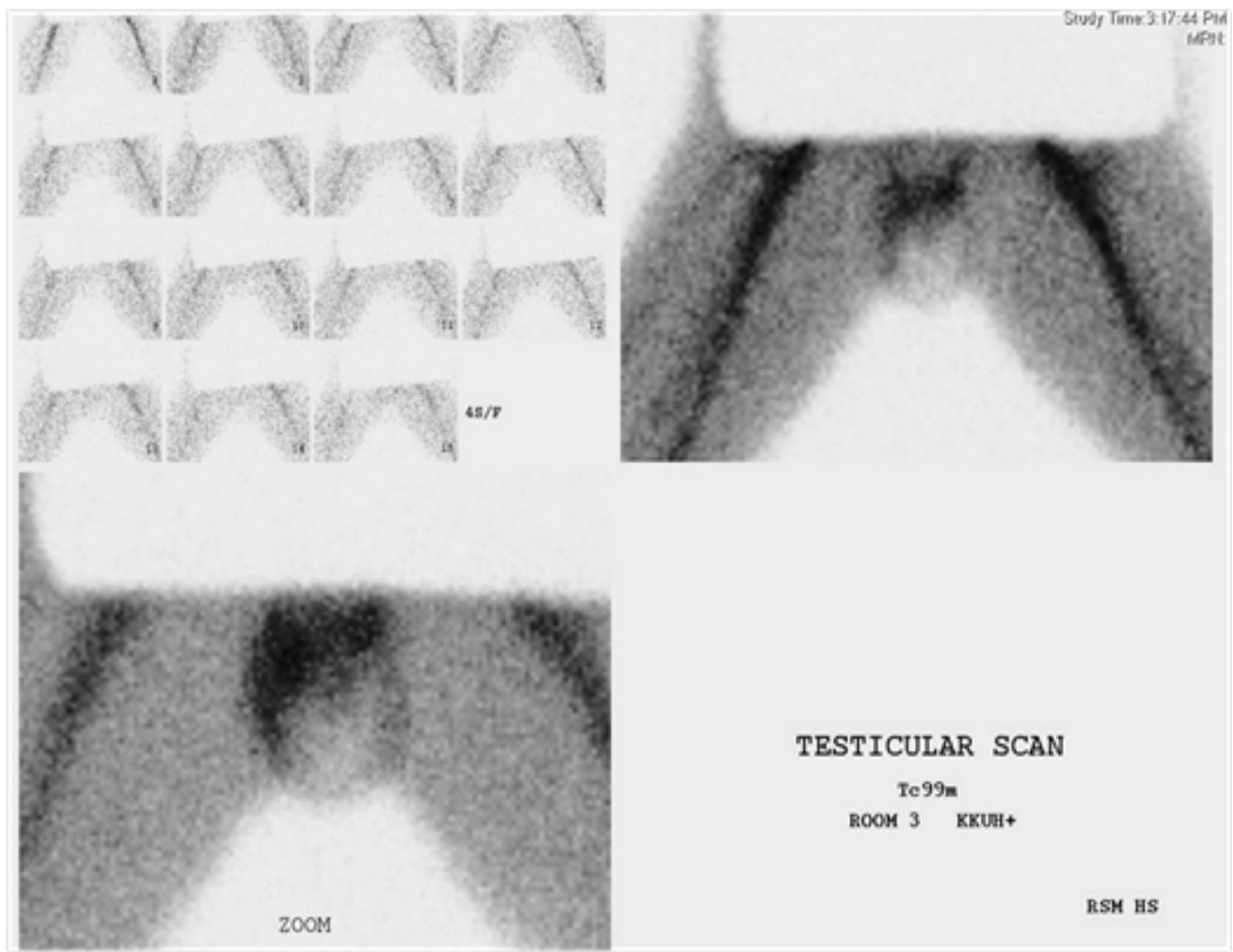


Figure 2. A 26 year old male patient who presented with right sided scrotal pain after an acute trauma (sports injury). Scan showed large photopenic area within the right testis Compatible with acute torsion.

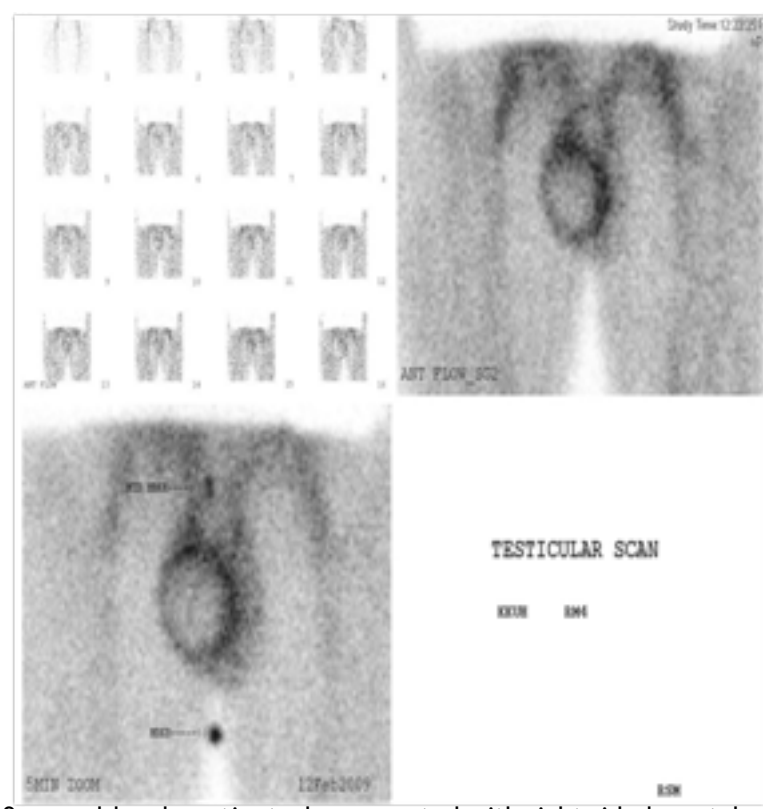
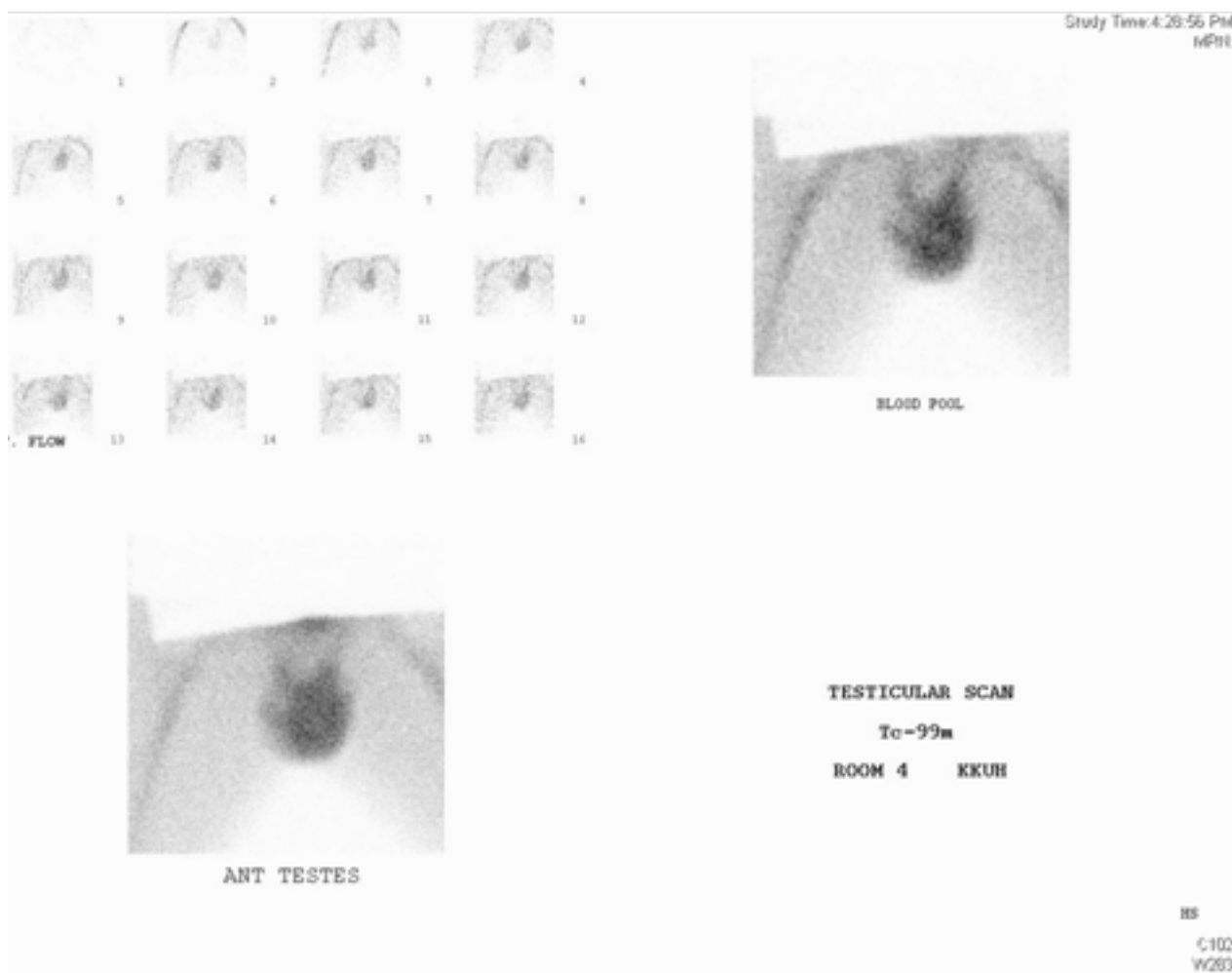


Figure 3. A 19 year old male patient who presented with right sided scrotal swelling. Scan shows enlarged right testicle and a central photopenic area surrounded by hyperemic rim (doughnut sign) compatible with missed torsion.



**Figure 4.** A 22 year old male patient who presented with left testicular pain. Scan shows increased blood flow and tracer concentration in left scrotum compatible with epididymo-orchitis.

Out of the seven true positive torsion cases, US examination raised the suspicion of torsion in five cases. In the remaining two cases, US examination was inconclusive (with further advice to correlate with scrotal scintigraphy). The one false-positive case on scrotal scintigraphy was thought to be missed torsion on US examination. In 5 patients ultrasound examination provided additional information (e.g. hydrocele).

**DISCUSSION**

Scrotal scintigraphy has played an important role in the management of acute scrotal emergencies. It is primarily used to differentiate testicular torsion from other pathological conditions causing acute scrotal pain. It is highly accurate in providing reliable results in confirming or excluding testicular torsion.<sup>11,12</sup>

In a normal scrotal scintigraphy, blood flow is faint but symmetrically visualized in the scrotum and testicles. However, when there is testicular torsion, reduced or absent delivery of radiotracer consequent upon obstruction of spermatic vessels will be evident and photopenia is seen in the corresponding hemi scrotum in early stages of testicular torsion. Abrupt cutoff of the iliac artery supplying the testicle may

occasionally be seen as nubbin sign.<sup>13</sup> In late stages of testicular torsion, referred as "missed torsion," reactive hyperemia around the affected testicle will give the appearance of doughnut sign or ring sign, a scintigraphic finding seen also in testicular abscess.

If a testicle spontaneously untwists (de-torsion) before imaging, there may actually be increased flow to that testicle due to hyperemia (with no photopenic center). The scintigraphic pattern in inflammation or infection is increased blood flow to the affected side and increased radiotracer concentration within the involved scrotum. It is therefore, important for the interpreting nuclear physician to be aware of the clinical presentation (lateralization of symptoms), as asymmetry in the blood flow and blood pool images may be due to abnormally increased uptake on one side, consistent with inflammation, or abnormally reduced uptake on the other side, consistent with torsion. Several other pathological entities may be encountered on the scan. A frank abscess or a tumor may mimic the appearance of missed torsion.<sup>14</sup>

Request for a scrotal scintigraphy in cases of acute scrotal pain always comes-up as an emergency



diagnostic procedure, requiring accurate and immediate answers to the clinical questions, whether the condition is surgical (e.g. torsion) or medical (e.g. inflammation). If a torsion is diagnosed well in time, then immediate surgical intervention to untwist the testicle is mandatory to rescue the testis. The salvage rate tends to reflect the time passed between the onset of the event and the surgical de-torsion. A salvage rate of 90-100% is reported if surgical intervention is done within six hours of the initial insult and dropped to 20% if surgery is delayed to more than 12 hours.<sup>4</sup>

In the present study, we found that scrotal scintigraphy gave 100% sensitivity to diagnose testicular torsion with a negative predictive value of 100%. Our results are in accordance with previous studies.<sup>15,16,17,18,19</sup>

In our study 67% of the cases fall in 11-30 years' age group. At this age, volume of the testicle increases and if there are predisposing congenital or developmental factors then testicles are prone to twist. During the fetal life, a portion of the peritoneal lining descends with testicles and provides covering to part of the testis (tunica vaginalis). The uncovered region of the testicle by this layer is anchored to the scrotum. If the tunica vaginalis covers too much of the testicle, it may be inadequately anchored to the scrotum ("bell clapper deformity"), allowing it to rotate within the scrotum. This is one of the major risk factor for testicular torsion with peak presentation around puberty. Other less common developmental abnormalities predisposing to testicular torsion are anomalous mesorchium, extra-long spermatic cord and abnormal separation of epididymis and testis.

In our study, the majority of cases presented in the months of February (n=6, 29%). That is probably due to the cold weather in this month leading to sudden temperature change. Sudden contraction of cremasteric muscle (especially if it is atypically long, and its fibers extend down more distally) during sleep or immediately after sleep. It has been reported that acute scrotum is more common during cold weather than in rest of the year.<sup>19,20,21</sup> In summer vacation where more outdoor activities and sports take place, there are also high chances of trauma to the testis which can present as torsion.

Scrotal ultrasound with Doppler is the first-line investigation and considered gold standard in evaluating acute scrotum.<sup>22</sup> However, US is an operator dependent procedure and expertise of the sonologists are vital. Sometimes the US result can be ambiguous, not confirming or excluding torsion (2 out of seven cases of torsion in the present study), and correlation with scintigraphy is suggested (5 out of seven cases in the present study). In such a situation, scintigraphy may bring a definite answer to the clinical query of testicular torsion.

## CONCLUSION

Scrotal scintigraphy in an acute scrotum is a feasible procedure to be performed on emergency basis, and it is a valid and reliable test to diagnose testicular torsion when US is doubtful or non conclusive. No specific patient preparation is required. Reporting is protocol based, and results are highly accurate. Total time required to perform the study is only 12-15 minutes, but it is essential to have it reported immediately. During the five-year period (data inclusion), the service was provided on an emergency basis with accurate results satisfying most of the referring physicians in our centre. This was accomplished by having a nuclear medicine physician and a nuclear medicine technologist on-call and contacted at any time.

## REFERENCES

1. Kapoor S. Testicular torsion: a race against time. *Int J Clin Pract* 2008; 62:821-7.
2. Abul F, Al-Sayer H, Arun N. The acute scrotum: a review of 40 cases. *Med Princ Pract* 2005; 14:177-81.
3. Cattolica EV, Karol JB, Rankin KN, Klein RS. High testicular salvage rate in torsion of the spermatic cord. *J Urol* 1982;128:66-8.
4. Donohue RE, Utley WL. Torsion of spermatic cord. *Urology* 1978;11:33-6.
5. Cimador M, Dipace MR, Castagnetti M, Degrazia E. Predictors of testicular viability in testicular torsion. *J Pediatr Urol* 2007;3:387-90.
6. Mushtaq I, Fung M, Glasson MJ. Retrospective review of paediatric patients with acute scrotum. *ANZ J Surg* 2003;73:55-8.
7. Seng YJ, Moissinac K. Trauma induced testicular torsion: a reminder for the unwary. *J Accid Emerg Med* 2000;17:381-2.
8. Gatti JM, Patrick Murphy J. Current management of the acute scrotum. *Semin Pediatr Surg* 2007;16:58-63.
9. Merrot T, Chaumoitre K, Robert A, Alessandrini P, Panuel M. Acute scrotum in children: radioclinic correlation. *Prog Urol* 2009;19:176-85.
10. Pavlica P, Barozzi L. Imaging of the acute scrotum. *Eur Radiol* 2001;1:220-8.
11. Haynes BE, Bessen HA, Haynes VE. The diagnosis of testicular torsion. *JAMA* 1983;249:2522-27.
12. Ringdahl E, Teague L. Testicular torsion. *Am Fam Physician* 2006; 74:1739-43.
13. Holder LE, Melloul M, Chen D. Current status of radionuclide scrotal imaging. *Semin Nucl Med* 1981;11:232-49.
14. Vieras F, Kuhn CR. Nonspecificity of the "rim sign" in the scintigraphic diagnosis of missed testicular torsion. *Radiology* 1983;146:519-22.
15. Karadeniz T, Topsakal M, Ariman A, et al. Prospective comparison of colour Doppler

- ultrasonography and testicular scintigraphy in acute scrotum. *Int Urol Nephrol* 1996;28:543-8.
16. Joyce JM, Grossman SJ. Scrotal scintigraphy in testicular torsion. *Emerg Med Clin North Am* 1992; 10:93-102.
  17. Nussbaum Blask AR, Bulas D, Shalaby-Rana E, et al. Color Doppler sonography and scintigraphy of the testis: a prospective, comparative analysis in children with acute scrotal pain. *Pediatr Emerg Care* 2002;18: 67-71.
  18. Yuan Z, Luo Q, Chen L, Zhu J, Zhu R. Clinical study of scrotum scintigraphy in 49 patients with acute scrotal pain: a comparison with ultrasonography. *Ann Nucl Med* 2001;15:225-9.
  19. Al-Hunayan AA, Hanafy AM, Kehinde EO, et al. Testicular torsion: a perspective from the Middle East. *Med Princ Pract* 2004;13:255-9.
  20. Anderson JB, Williamson RC. Testicular torsion in Bristol: a 25-year review. *Br J Surg* 1988;75:988-92.
  21. Williams CR, Heaven KJ, Joseph DB. Testicular torsion: is there a seasonal predilection for occurrence? *Urology* 2003;61:638-41.
  22. Hod N, Maizlin Z, Strauss S, Horne T. The relative merits of Doppler sonography in the evaluation of patients with clinically and scintigraphically suspected testicular torsion. *Isr Med Assoc J* 2004; 6:13-5.

