

A Puzzling Case of Biliary Stricture with Calcified Liver Nodules

Leow VM^a, Faizah MS^b, Yang KF^c, Hasnan MN^c, Manisekar SS^c

^aOncology Cluster, Advanced Medical and Dental Institute (AMDI), Universiti Sains Malaysia, Penang, Malaysia

^bDepartment of Surgery, Sultanah Bahiyah Hospital, Alor Setar, Kedah, Malaysia

^cHepatobiliary Unit, Department of Surgery, Sultanah Bahiyah Hospital, Alor Setar, Kedah, Malaysia

ABSTRACT

Tuberculous (TB) biliary stricture with calcified liver nodules rendering obstructive jaundice is a rare clinical phenomenon. Recently, we encountered a young patient with obstructive jaundice who was investigated in a general hospital. He was sent to our hospital for subsequent management after undergoing a series of investigations and biliary stenting. The radiological imaging performed revealed multiple calcified lesions in the liver with proximal bile duct strictures. Blood investigations, tumor markers and tuberculous work up were not remarkable. Subsequently, he underwent laparotomy and biliary reconstruction. Postoperatively, he was discharged well. Histopathological examination of the hepatoduodenal nodes showed chronic infections and granulomatous lymphadenitis, suspicious of a mycobacterium infection.

KEYWORDS: Biliary Tuberculosis, biliary stricture, calcification, liver nodules, cholangiocarcinoma

INTRODUCTION

Hepatobiliary tuberculosis is uncommon and it can mimic liver tumors causing biliary obstruction, cholangiocarcinoma, and periampullary tumors. The clinical presentations can be misleading. This explained the different modes of diagnostic and treatment regimens ranging from endoscopic or

antegrade biliary stenting to surgical biliary reconstruction. Because of that the diagnosis is often established at operation, after the surgery via histology or by PCR assay. Invariably, the treatment mandates anti-tubercular therapy.

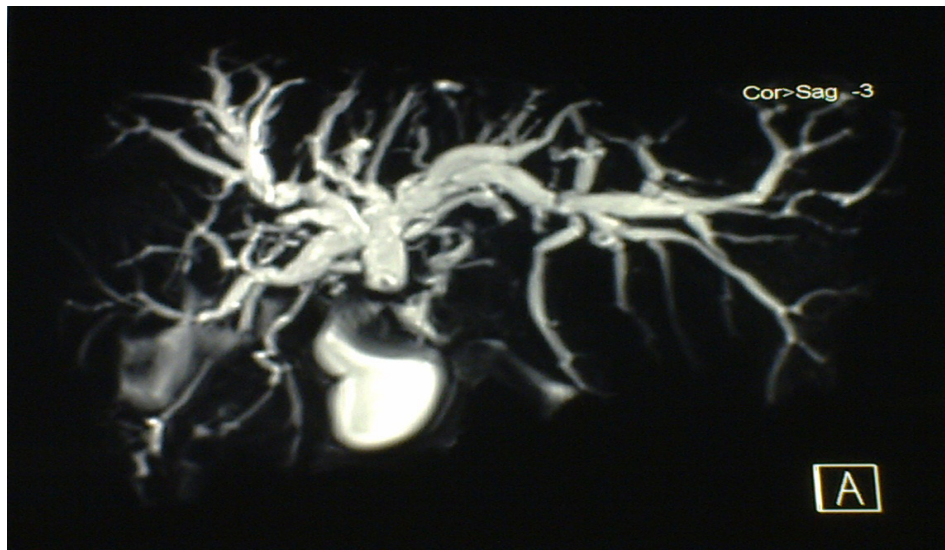

Figure 1. MRCP revealed stricture at common hepatic duct

Corresponding author:

Dr Leow Voon Meng
General Surgeon/ Lecturer of Surgery
Advanced Medical and Dental Institute (AMDI)
Universiti Sains Malaysia, Bandar Putra Bertam
13200, Kepala Batas, Penang, Malaysia.
Tel: 604-5622005, 604-5622046
Fax: 604-5622461, 604-5622462
Email: leowvm@amd.i.usm.edu.my

CASE REPORT

A 26-year-old gentleman who works as a teacher was referred from Queen Elizabeth Hospital, Sabah (West Malaysia), to Sultanah Bahiyah Hospital, Kedah, Hepatopancreatic Biliary Center, northern state of Peninsular Malaysia on February 2011 for management of obstructive jaundice. The patient presented with a two-month history of right hypochondriac and epigastric pain associated with fever. Later, he had jaundice, tea-colored urine and pale colored stool.

His physical findings were not significant except for the jaundice. Work-ups for tuberculosis were all negative. Liver function test revealed the obstructive picture. The Ca 19-9 and CEA were within normal limits. His upper and lower gastrointestinal scopes were unremarkable. Endoscopic retrograde cholangiopancreatography (ERCP) was carried out, which demonstrated stricture formation at the hepatic duct confluence. Magnetic resonance cholangiopancreatography (MRCP) showed a stricture at the proximal common bile duct (figure 1). A three-phase computed to-

mography (CT) of the liver was also done displayed hepatolithiasis with multiple calcified periportal lymphadenopathy (figure 2). The blood investigations taken at our centre did not show any significant abnormality except for elevated C-reactive protein (CRP). His hemoglobin level was 15.4 g/dL, white cell count was 11 000, renal profile was normal, albumin was 44 mmol/L, total bilirubin was 18 μmol/L, ALP was 276 u/L, gamma GT was 246 u/L, ALT was 91 u/L, ESR was 1.0 mm/hr and CRP was 68 mg/L.

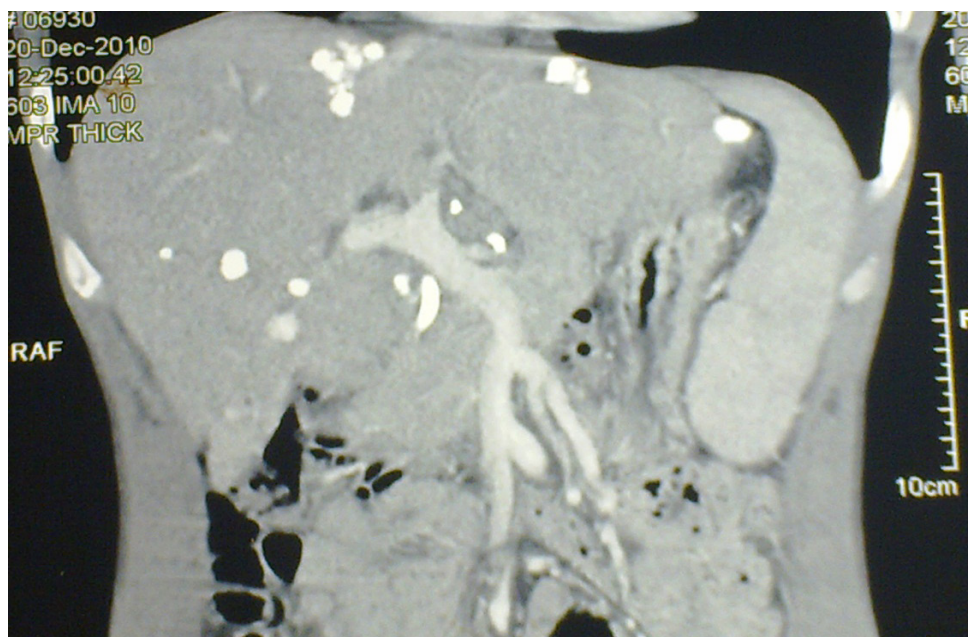


Figure 2. Coronal view of CT liver displayed hepatic calcifications situated at the liver surface

Subsequently, he underwent laparotomy, intraoperative choledochoscopy, choledochectomy and Roux-en-Y hepaticojejunostomy. The operative findings were dilated intrahepatic ducts bilaterally with common hepatic duct stricture, hepatoduodenal lymphadenopathy and multiple hard whitish-yellow liver nodules (figure 3). They were not typical of secondaries and could be of inflammatory in origin. Liver was not cirrhotic, and no biliary stone was seen. Post operatively, the patient recovered well. Bile for AFB was negative. He was discharged back to his

hometown in Sabah as requested by the patient. His histopathological examination report of the hepatoduodenal lymph nodes revealed granulomatous lymphadenitis with suspicious of a mycobacterium infection. Liver nodules were calcified. Both the gallbladder and common bile duct were consistent with chronic cholecystitis and chronic cholangitis respectively. He was started on anti-tubercular treatment. The patient was followed up and was doing well.

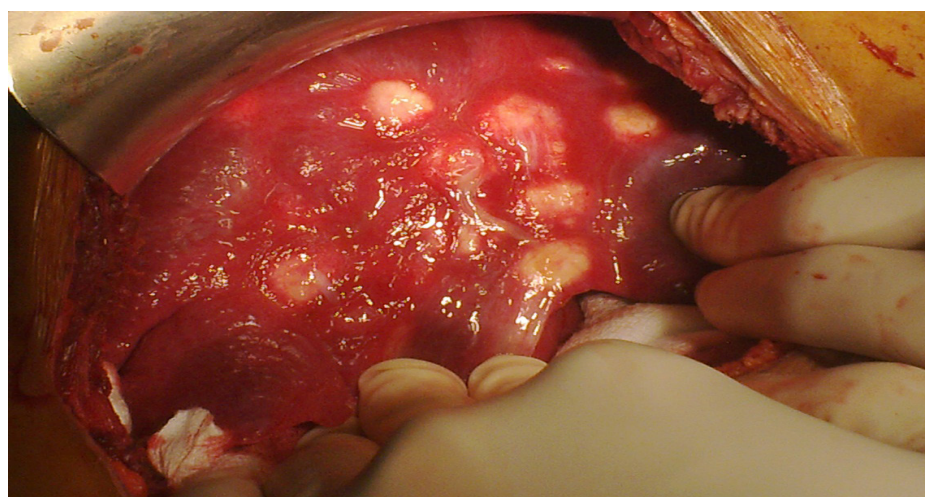


Figure 3. Intraoperative photograph of multiple calcified liver nodules seen on CT images

DISCUSSION

Abdomen is one of the common extrapulmonary manifestations of disseminated tuberculous infection.¹ *Mycobacterium tuberculosis* infects the biliary system via hematogenous route from the lungs or lymphatics from another intra-abdominal source of infection. The common bile duct involvement is thought to be the result of the spread of caseous material from the portal tract or secondary inflammation related to

periportal adenitis.² Tubercular biliary strictures can be classified as type 1, 2, 3 and further sub-classified into intrinsic or extrinsic according to the location and nature of the obstruction (table 1). Left untreated, biliary tuberculosis can lead to cholestasis, recurrent cholangitis (overt or subclinical), secondary biliary cirrhosis and secondary hepatolithiasis.²

Table 1. Types of Tubercular Biliary Strictures

	Intrinsic (Intramural)	Extrinsic (Nodal)
Type 1, Extrahepatic	Common bile duct stricture	Compression by enlarged pericholedochal lymph nodes
Type 2, Intrahepatic	Intrahepatic strictures	Compression by enlarged perihilar lymph nodes
Type 3, Combined	Extrahepatic and intrahepatic strictures	Combination of biliary strictures and lymph node compression

Source: Sriram PV, Rao GV, Reddy DN. Endoscopic management of benign biliary obstruction. Available at www.bhj.org/journal/2002_4404_oct/therap_543.htm. Accessed 4 Jan 2007.

The most common cause of hepatic calcification is due to granuloma formation as a result of inflammatory condition. Most of the patients who have these lesions are clinically asymptomatic. This represents previous infection in the liver either from tuberculosis or histoplasmosis. Calcified granulomas are usually small lesions and less than 2 cm in diameter. They may be solitary or multiple as seen in our patient. The calcification typically involves the entire lesion which appears as a dense mass that can produce artifacts in the CT image.³

Cytology or tissue diagnosis is crucial for the diagnosis of biliary tuberculosis. The specimens can be obtained by endoscopic brush cytology/ biopsy⁴ or by fine needle biopsy of involved lymph nodes using ultrasound or CT guided percutaneous procedure.⁵ Polymerase chain reaction (PCR) assay is another alternative method of demonstrating mycobacterial DNA.⁶ Other diagnostic tool, include obtaining tissue specimens by laparoscopic technique or endoscopic ultrasound (EUS) FNA.⁷

The clinical dilemma that we faced was the possibility of malignancy in this patient. In addition, there was no clinical and biochemical evidence of tuberculous infection. Based on the literature review the diagnosis of tuberculous infection of the biliary system is encountered in a variety of settings. They are often established at operation; post operatively by histology or by PCR technique.⁸

The treatment of tuberculosis of the biliary tree is antitubercular therapy. This should combine with

endoscopic sphincterotomy, dilatation and stenting if the biliary system is obstructed.⁹ The antitubercular regimen for extrapulmonary tuberculosis is recommended by the World Health Organization and the Joint Statement of American Thoracic Society, Centers for Disease Control and Prevention and the Infectious Diseases Society of America.¹⁰ Generally, the treatment regimen requires a duration of 6-9 months, with 2 months of isoniazid, rifampicin, pyrazinamide and ethambutol, followed by 4-7 months of isoniazid and rifampicin.¹⁰

We conclude that the clinical presentation of this disease entity can be challenging. A high index of suspicion and perseverance are essential in pursuing the diagnosis of biliary tuberculosis followed by antitubercular treatment.

CONFLICT OF INTEREST

None declared.

REFERENCES

1. Marshall JB. Tuberculosis of the gastrointestinal tract and peritoneum. *Am J Gastroenterol* 1993; 88:989-9.
2. Sriram PV, Rao GV, Reddy DN. Endoscopic management of benign biliary obstruction. [online] Available at www.bhj.org/journal/2002_4404_oct/therap_543.htm. Accessed 4 Jan 2007.
3. Paley MR, Ros PR. Hepatic calcification. *Radiol Clin North Am* 1998; 36:391-8.
4. Bearer EA, Savides TJ, McCutchan JA. Endoscopic diagnosis and management of hepatobiliary

- tuberculosis. *Am J Gastroenterol* 1996; 91:2602-4.
5. Probst A, Schmidbaur W, Jechart G, et al. Obstructive jaundice in AIDS: diagnosis of biliary tuberculosis by ERCP. *Gastrointest Endosc* 2004; 60:145-8.
 6. Anand BS, Schneider FE, El-Zaatari FA, et al. Diagnosis of intestinal tuberculosis by polymerase chain reaction on endoscopic biopsy specimens. *Am J Gastroenterol* 1994; 89:2248-9.
 7. Woodfield JC, Windsor JA, Godfrey CC, et al. Diagnosis and management of isolated pancreatic tuberculosis: recent experience and literature review. *ANZ J Surg* 2004; 74:368-71.
 8. Xia F, Poon RT, Wang SG, et al. Tuberculosis of pancreas and peripancreatic lymph nodes in immunocompetent patients: experience from China. *World J Gastroenterol* 2003; 9:1361-4.
 9. Alvarez S. Hepatobiliary tuberculosis. *J Gastroenterol Hepatol* 1998; 13:833-9.
 10. Blumberg HM, Burman WJ, Chaisson RE, et al. American Thoracic Society/ Centers for Disease Control and Prevention/ Infectious Diseases