

# A Rare Case of Primary Extranodal Laryngeal Non Hodgkin Lymphoma

Mark P.<sup>1</sup>, Najihah Hanim A.<sup>1</sup>, Eshamsol Kamar O.<sup>1</sup>, Suhaila A.<sup>2</sup>, Irfan M.<sup>3</sup>

<sup>1</sup> Department of Otorhinolaryngology, Hospital Sultan Haji Ahmad Shah, 28000, Temerloh, Pahang, Malaysia.

<sup>2</sup> Department of Pathology, Hospital Tengku Ampuan Afzan, 25100, Kuantan, Pahang, Malaysia.

<sup>3</sup> Department of Otorhinolaryngology-Head & Neck Surgery, School of Medical Sciences, Universiti Sains Malaysia Health Campus, 16150 Kota Bharu, Kelantan, Malaysia.

## ABSTRACT

Lymphoma is generally a nodal disease and arises from lymphoid tissues or organs. Extranodal lymphoma accounts for almost a third of malignant lymphomas. Squamous cell carcinoma accounts for 90 % of laryngeal carcinoma, while extranodal Non Hodgkin Lymphoma (NHL) attributes only less than 1% of laryngeal neoplasms. Less than 100 of such cases been reported in literature since 1952. As to our best knowledge, no such case was ever reported in our country. We report a case of a 58-year-old gentleman who presented the typical history of laryngeal malignancy however the pathology turned out to be as NHL of Diffuse Large B-cell subtype.

**KEYWORDS:** laryngeal neoplasm; lymphoma, B-Cell; Non Hodgkin.

## INTRODUCTION

Lymphoma is a malignancy that originates from abnormal lymphoid cells and generally affects the lymph nodes and lymphoid organs. Gastrointestinal tract and cutaneous lymphoma accounts for most of the malignant lymphomas followed by extranodal lymphomas at 30-40 % of cases.<sup>1</sup> Extranodal Non Hodgkin Lymphoma (NHL) attributes a very minor fraction of laryngeal carcinoma. A Review of literatures revealed several subtypes of NHL of the larynx have been reported with mostly being Diffuse Large B-cell subtype followed by in no specific order: marginal zone lymphoma subtype, T-cell lymphoma subtype, natural killer (NK) cell lymphoma subtype<sup>2</sup> and mantle cell lymphoma.<sup>3</sup>

## CASE SUMMARY

A 58-year-old gentleman, an ex-intravenous drug user and active smoker, presented with one-month history of progressive hoarseness but without

respiratory problem. He had progressive dysphagia and was only able to tolerate semisolid and fluid diets. There was no history of neck mass, trauma or previous surgeries. There was no corrosive agent ingestion. There was no fever, significant weight loss or loss of appetite. Examination of his neck revealed no scar, no neck swelling and no enlarged lymph nodes palpable. The cough was weak and maximum phonation time slightly shortened.

Flexible nasoendoscopy revealed a limited view of a fungating mass at left aryepiglottic fold involving left arytenoid. The epiglottis was retroflexed during inspiration obscuring bilateral vocal cords causing suboptimal assessment of the vocal cords. Tonsils and adenoid were not enlarged.

The computed tomographic (CT) scan of the neck revealed a soft tissue density mass arising from the epiglottis extending to the right preepiglottic, paralaryngeal space and effaced the valleculae (Figure 1). Involvement of bilateral aryepiglottic folds effaced the pyriform sinus, bilateral true and false vocal cords. Paranasal sinuses and thyroid gland were normal. There was no cervical lymphadenopathy seen.

He underwent an elective tracheostomy under local anesthesia followed by examination of the larynx

Corresponding author:

Dr. Mark Paul

Department of Otorhinolaryngology

Hospital Sultan Haji Ahmad Shah

28000 Temerloh Pahang

Malaysia

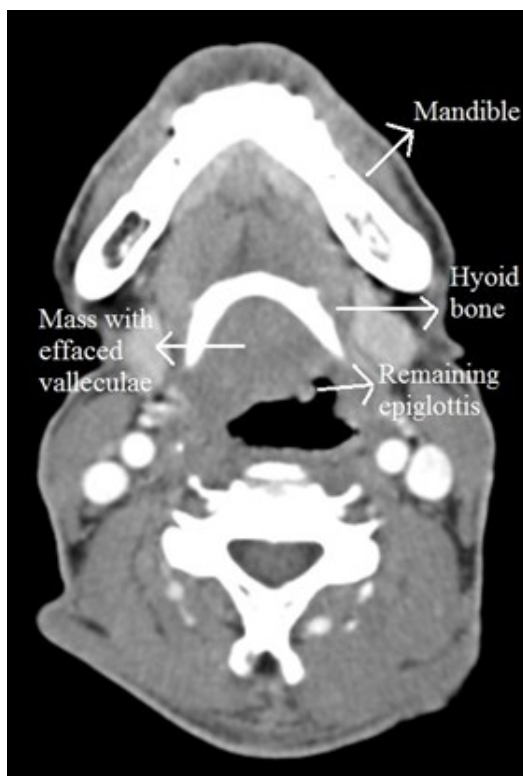
Tel No: 016-3488438

Email : markpaul3288@gmail.com

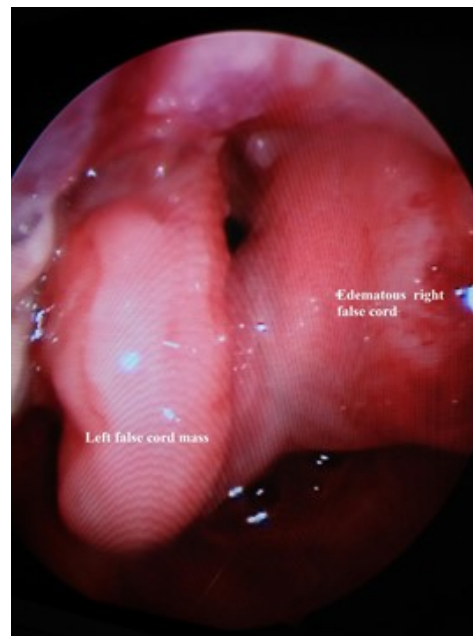
under general anesthesia. Direct laryngoscopy revealed a mass at left false cord extending to left arytenoid, left valleculae and left laryngeal surface of epiglottis (Figure 2a & 2b). The right false cord and right arytenoid were edematous. Bilateral true cords, subglottic, post cricoid and anterior commissure appeared normal.

On the post-operative day 2, he developed respiratory distress and septic shock secondary to hospital acquired pneumonia (HAP) requiring mechanical ventilation. His blood parameters were within normal range and he was negative for Human Immunodeficiency Virus (HIV). He was treated with intravenous piperacilin-tazobactam antibiotic, but unfortunately, he succumbed to the infection shortly after.

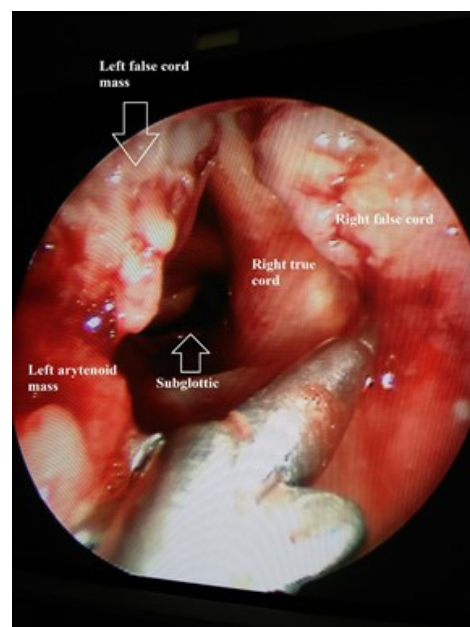
His histopathological report based on sampled biopsies from left arytenoid, left laryngeal surface of epiglottis and left valleculae revealed malignant lymphoid cells that are positive for CD20, CD79A, BCL2 and focal positive for BCL6 but are negative for CD3, CD10 (Figure 3). Immunohistochemical stain revealed proliferative index (Ki 67) was about 60-70%, thus establishing the diagnosis of laryngeal NHL of Diffuse Large B-cell subtype. No malignancy was detected from biopsies of right arytenoid and right false cord.



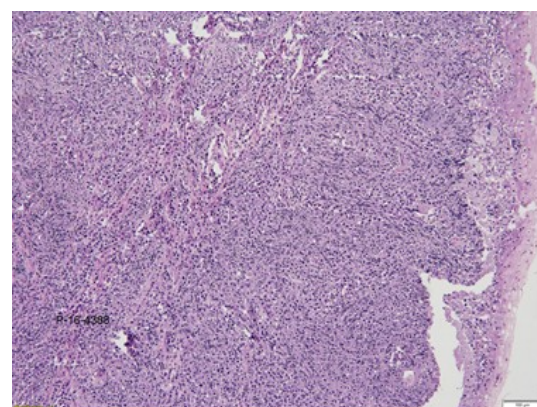
**Figure 1.** CT scan of neck, axial view showed soft tissue mass with slight enhancement arising from the epiglottis extending to the right preepiglottic space effacing the valleculae.



**Figure 2a:** Edematous right false cord and left false cord mass seen upon introduction of rigid direct laryngoscope.



**Figure 2b:** Spreading false cords revealed mass at left false cord extending to left arytenoid. Normal structures were seen beyond the false cords



**Figure 3:** The malignant lymphoid cells infiltrating into the stroma in diffuse pattern (H&E stain, X200 magnification).

## DISCUSSION

The primary extranodal laryngeal NHL is rare in that only 1 case was detected out of 2631 laryngeal biopsies done at a tertiary center in Spain over the span of 10 years.<sup>4</sup> Incidence was reported in both healthy and immunocompromised groups of patients without any specific predilection.

Most affected anatomical location is a supraglottic region (47%) followed by glottic involvement (25%) while transglottic and subglottic region being the least affected.<sup>4</sup>

Extranodal NHL in the context of ENT usually affects the salivary glands, paranasal sinuses and thyroid gland<sup>4</sup>. The low incidence rate is because larynx has very little lymphoid tissues compared to the gastrointestinal tract and respiratory tract. The larynx has lymphoid tissue aggregates in the submucosa, mostly being B-cell lineage and Mucosal Associated Lymphoid Tissue (MALT) in epiglottis and aryepiglottic folds.<sup>5</sup>

Presentation of primary laryngeal lymphoma is the same as laryngeal squamous cell carcinoma. The symptoms include hoarseness, stridor, dyspnea and constitutional symptoms.

Due to the small number of cases, no proper and definitive management guidelines, success rates and prognosis have been published. Modalities of treatments were concurrent chemoradiotherapy or just radiotherapy. Eight cycles of CHOP (cyclophosphamide, doxorubicin, vincristine, prednisolone) chemotherapy regime and weekly rituximab for 4 weeks<sup>6</sup> or 3 cycles of the same chemotherapy regime followed by external radiotherapy at a dose 30-50 Gy are recommended. This is the general first-line treatment regime for any NHL.<sup>2,4,5,6</sup> Tracheostomy is performed in those patients who presented with acute airway obstruction. Unfortunately, our patient succumbed to hospital-acquired pneumonia (HAP) before he could be commenced on treatment.

Review of literature revealed this disease has rather high 5-year disease-free rate of 70% and low recurrence rate of less than 30%<sup>1-7</sup> except for the mantle cell lymphoma subtype, which is very aggressive with poor prognosis. Only one mantle cell lymphoma case has been reported.<sup>3</sup>

## CONCLUSION

Primary laryngeal lymphoma is very rare and it presents exactly like other laryngeal carcinoma. It responds very well to chemotherapy and radiotherapy. The prognosis of this disease is good if it is detected early and commenced on treatment appropriately.

No specific management guidelines exist for this disease due to its low incidence rate. The latest international lymphoma treatment guideline should be adapted into our management if we detect such cases. As such, life-long follow up of these patients is imperative for early detection of possible recurrence and to act appropriately.

## REFERENCES

1. Feller AC, Diebold J. Histopathology of Nodal and Extranodal Non-Hodgkin's Lymphomas. (2004) Springer Berlin Heidelberg, pp. 186-363.
2. Azzopardi CP, Degaetano J, Betts A, Farrugia E, Magri C, Refalo N. et al. Laryngeal Lymphoma: The High and Low Grades of Rare Lymphoma Involvement Sites. *Case Rep Med* 201; Article ID 284643.
3. Naciri S, Bennani-Baiti AA, Glaoui M, Mouzount H, Ghanem S, Essakali L. et al. Mantle cell lymphoma of the larynx: Primary case report. *J Med Case Rep* 2012; 6:201.
4. Markou K, Goudakos J, Constantinidis J, Kostopoulos I, Vital V, Nikolaou A. Primary laryngeal lymphoma: report of 3 cases and review of the literature. *Head Neck* 2010; 32: 541-9.
5. Ansell SM, Habermann TM, Hoyer JD, Strickler JG, Chen MG, McDonald TJ. Primary laryngeal lymphoma. *Laryngoscope* 1997; 107: 1502-6.
6. Word R, Urquhart AC, Ejercito VS. et al. Primary laryngeal lymphoma: Case report. *Ear Nose Throat J.* 2006; 85: 109-11.
7. Khamassi K, Mahfoudhi M, Jaafoura H, Ouertani K, Kaabachi W, Bougacha L. et al. Primary Lymphoma of the Larynx: A Case Report and Literature Review. *Open J Clin Diagn* 2015; 5: 81-5.

