

Nutritional Rickets in Three Toddlers during Covid-19 Pandemic Lockdown

Lee YL^a, Yusoff NA^b, Ting TH^a

^aPaediatrics Endocrine Unit, Department of Paediatrics, Hospital Sultan Abdul Aziz Shah, Universiti Putra Malaysia, Serdang, Selangor, Malaysia

^bDepartment of Paediatrics, Universiti Putra Malaysia, Serdang, Selangor, Malaysia

ABSTRACT

Nutritional rickets is a worldwide problem which has been increasingly reported globally. Three toddlers aged 1-2 years presented in March to April 2021 with bony deformities following one year of national Covid-19 pandemic lockdown since March 2020. All three patients were breastfed till presentation without formula milk supplementation. Weaning occurred at 4-6 months of age but without proper complementary food intake. All three patients and their nursing mothers were mostly confined indoors during the pandemic lockdown. Bone metabolic profile and radiological imaging confirmed vitamin D deficiency rickets. All three patients responded well to vitamin D3 treatment and calcium supplementation for 3-6 months duration. Vitamin D deficiency rickets appears to be an increasing problem in breastfed toddlers following the prolonged movement control order, particularly amongst picky eaters and young children on restrictive diets. Sun exposure and early vitamin D supplementation are crucial to prevent the development of nutritional rickets.

Keywords

Nutritional rickets, Covid-19 pandemic lockdown, picky eaters, vitamin D deficiency

Corresponding Author

Dr. Yee Lin Lee
Paediatrics Endocrine Unit,
Department of Paediatrics,
Hospital Sultan Abdul Aziz Shah,
Universiti Putra Malaysia,
43400, Serdang, Selangor, Malaysia
E-mail: yeelin@upm.edu.my

Received: 16th March 2022; Accepted: 2nd Aug 2022

Doi: <https://doi.org/10.31436/imjm.v22i3>

INTRODUCTION

Nutritional rickets remains a major public health concern worldwide despite a better understanding of the underlying cause and pathogenesis. Vitamin D deficiency rickets commonly presents in the first year of life, peaking in incidence between 3-18 months of age while rickets associated with calcium deficiency presents later after 1 year of age.¹ During the first 12 months of life, infants with vitamin D deficiency can present with symptoms of hypocalcaemia, namely seizures and tetany.¹

Older infants and toddlers usually present with widened wrist, frontal bossing and rachitic rosary.¹ When infants start to weight bear or walk, they commonly present with bowing of both lower limbs.¹ In this case series, three toddlers aged 1-2 years who were fully breastfed presented with bony deformities between March and April 2021 following one year of national Covid-19 pandemic lockdown since March 2020. All three patients and their nursing mothers were mostly confined indoors with minimal sun exposure during the pandemic lockdown.

CASE PRESENTATION

Patient 1, a 15-month-old girl had bilateral wrist swelling for one month with faltering growth. Weaning had occurred at 6 months of age but up till presentation, she was mostly dependent on breastmilk with minimal complementary diet intake. She only managed to take 1-2 spoonsful of rice with minimal chicken or fish during each meal and would spit out the food if given more.

Patient 2, a 20-month-old boy had leg bowing for two months with faltering growth. He was still breastfeeding without formula milk supplementation. Even though he was on a varied complementary diet introduced from 6 months of age, consisting of rice, chicken, vegetable, bread and fruits, the caloric amount was inadequate.

Patient 3, aged 12 months presented with leg bowing for two months. He has had eczema since 3-months-old. He was still breastfeeding and had previously experienced eczema flare ups whenever his nursing mother consumed dairy products. Hence, he was on a complementary diet

restricted to rice or porridge with pureed vegetables or fruits but devoid of cow's milk, meat, and dairy products.

Physical examination revealed frontal bossing, widened wrists, rachitic rosary and genu varum in all three patients (Figure 1). In addition, Patient 1 had enamel hypoplasia. Bone metabolic profile in the three patients confirmed vitamin D deficiency rickets evidenced by normal serum calcium, low serum phosphate, raised alkaline phosphatase (ALP), raised parathyroid hormone (PTH) and low 25-hydroxyvitamin D levels (25(OH)D) (Table 1). Radiographs of bilateral wrists and knees revealed florid rickets. (Figures 2A and 2B). Patient 1 and Patient 3 had concurrent iron deficiency anaemia evidenced by hypochromic microcytic anaemia and low serum iron (Table 1).

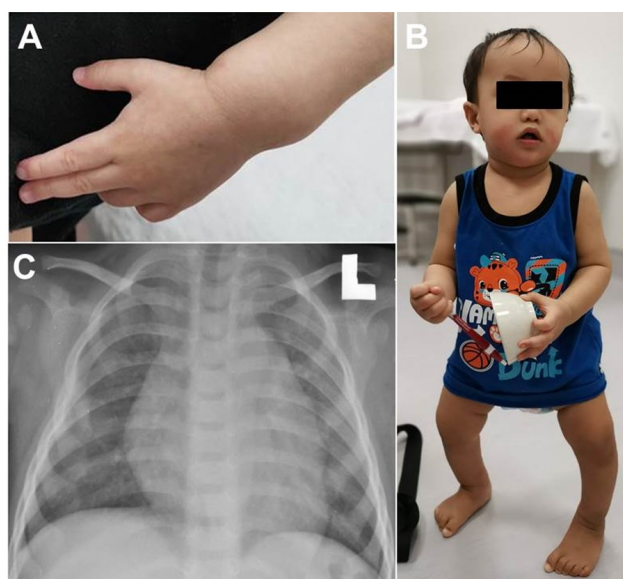


Figure 1: (A) Left wrist swelling in patient 1. (B) Severe bowing of both lower limbs and frontal bossing in Patient 3. (C) Chest radiograph showing splaying and fraying of distal anterior ribs in Patient 2 with rachitic rosary

Table 1: Presentation and serial biochemistry of patients in case series

	Patient 1		Patient 2		Patient 3	
	Baseline	3month	Baseline	5month	Baseline	7month
Wt (z-score)	6.8kg (-4.23SD)	7.8kg (-3.54SD)	9.5kg (-2.25SD)	11.1kg (1.35SD)	9.34kg (-0.9SD)	12kg (0.08S)
Lt (z-score)	70.5cm (-2.15SD)	73.5cm (-2.09SD)	78cm (-1.78SD)	84.6cm (0.97SD)	76cm (0.16SD)	86cm (0.94S)
Wt for Lt (z-score)	-2.83SD	-2.01SD	-1.12SD	-0.84SD	-0.72SD	-0.14SD
Ca (mmol/L) (N 2.25-2.75)	2.3	2.35	2.34	2.41	2.25	2.56
PO4 (mmol/L) (N 1.00-1.95)	0.64	1.62	0.7	1.86	0.96	1.74
ALP (IU/L) (N 142-335)	2409	796	816	284	958	357
PTH (pmol/L) (N 1.59-7.24)	44.63	6.44	-	4.05	37.81	1.01
25(OH)D nmol/L (N> 50)	13.9		23.5		28.24	
Iron (µmol/L) (N 5.5-25.8)	2.9		7.7		3.9	

Wt, weight; Lt, length; SD, standard deviation; Ca, calcium; PO4, phosphate; ALP, alkaline phosphatase; PTH, parathyroid hormone; 25(OH)D, 25-hydroxyvitamin D

All three patients were treated with 2000-3000IU vitamin D3 and calcium supplementation for 3-6 months duration. In addition, Patients 1 and 3 required iron supplements. Patients 1 and 2 were started on high calorie formula milk for catch up growth. The parents were educated on foods containing calcium, vitamin D and iron as well as the importance of sunlight exposure. All 3 patients showed improvement in growth, bony deformities (Figures 2C and 2D) and bone metabolic markers after treatment (Table 1).

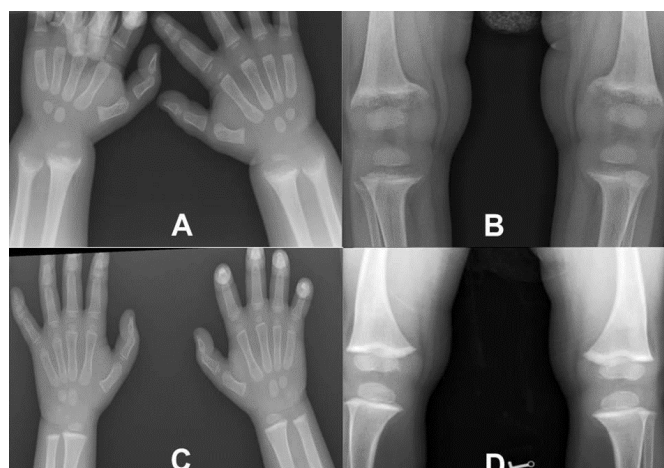


Figure 2: Bilateral knee and wrist radiographs showing splaying, fraying and cupping of radial, ulnar, femur and tibial metaphyseal ends before treatment (A & B) and resolving rickets 5 months after initiating treatment (C & D) in Patient 2

DISCUSSION

Nutritional rickets is a disorder of defective growth plate chondrocyte apoptosis and osteoid mineralization in children caused by vitamin D deficiency and/or calcium deficiency. In calcipenic rickets due to vitamin D or calcium deficiency, ALP rises and secondary hyperparathyroidism maintains normocalcaemia through renal calcium absorption in the expense of phosphate wasting. Vitamin D deficiency is common worldwide as it is only present in few food sources e.g., fatty fish, sun-dried mushrooms, cereals, dairy products, and egg yolk.

The major source of vitamin D is through epidermal ultraviolet B (UVB) absorption and conversion of 7-dehydrocholesterol to vitamin D₃. Several factors can affect UV light absorption, including dark skin pigmentation, sun avoidance and full body clothing cover. Hence, vitamin D deficiency remains prevalent even in sun abundant countries eg Africa, Asia and Middle East.² Infants who are breastfed exclusively are at higher risk of vitamin D deficiency compared to infants on formula milk due to poor penetrance of 25(OH)D into breastmilk and possible maternal vitamin D deficiency.³ The lack of sunlight exposure among the lactating mothers during the pandemic lockdown puts them at risk of vitamin D deficiency if they have not been on vitamin D supplementation during pregnancy and lactation.³

Calcium deficiency commonly co-exists with vitamin D deficiency rickets and is a common cause of nutritional rickets in developing countries.⁴ The calcium, iron and zinc content of complementary foods provided to children in Asia, Africa, and Latin America during the first year has been found to be well below 50% of recommended daily requirements.⁵ Similarly, a nutritional survey conducted among Malaysian children aged 6 months to 12 years revealed that vitamin D and calcium intake were below recommendations in 50% of the children.⁶ In high income countries, the resurgence of nutritional rickets has been observed amongst immigrants of Asians, Africans and Middle Eastern origins due to low dietary calcium or sun avoidance.⁷ A recent systematic review showed that Asians had a negative attitude towards dairy products due to lactose intolerance, aversion to the taste and poor awareness on importance of calcium and vitamin D for bone health.⁸ Co-existing calcium deficiency lowers the threshold for rickets development in patients with vitamin D deficiency.¹

The three patients illustrated here most likely have vitamin D deficiency contributed by the home confinement with no outdoor sun exposure during the movement control order. In addition, they were likely to have concurrent calcium deficiency due to prolonged breastfeeding without a sufficient well-balanced complementary diet. The dietary recall in these three patients showed that their diets were not only deficient in cow's milk and dairy products, but

also low in meat, fish, cereals and vegetables, predisposing them also to iron deficiency, as seen in Patients 1 and 3. Lack of physical medical consultations at local health clinics during the prolonged pandemic lockdown could have led to delayed detection of faltering growth and undernutrition, resulting in the missed opportunity for earlier nutritional intervention and prevention of rickets.

The recommended 25(OH)D level for sufficient Vitamin D status from the global consensus statement 2016 and the Malaysian recommended nutrient intakes (RNI) report 2017 is >50nmol/L.^{9,10} When 25(OH)D falls below 30nmol/L, there is an increased risk of developing nutritional rickets.⁷ The global consensus statement and Malaysian RNI report recommends vitamin D 400IU/ day to be given to all infants below 1 year of age irrespective of feeding mode to prevent nutritional rickets.^{9,10} In addition, complementary food rich in calcium should be introduced by 6 months of age, aiming for calcium intake of 260mg/day between 7 to 12 months of age.^{9,10} Beyond 1 year of age, all children and adolescents need to meet calcium intake of least 500mg/day and vitamin D intake of at least 600IU/day.⁹ The Malaysian RNI for calcium in children is 700mg/day for 1-3 years old and 1000mg/day for 4-9 years old.¹⁰ For the treatment of nutritional rickets, a minimal dose of vitamin D 2000IU/day for at least 3 months is recommended.⁹ Oral calcium 500mg/day should be routinely given concurrently either as dietary intake or supplementation.⁹

Health practitioners at local health clinics can identify infants/toddlers at risk of calcium and vitamin D deficiencies by incorporating diet recall as part of health screening. This can be performed during routine health clinic follow-up for growth monitoring and immunisation. Parents need to be educated on complementary foods that are rich in calcium and vitamin D. Small fish with bones (sardine, tunas), soybeans (tofu and tempeh), beans and green leafy vegetables (mustard leaves, spinach, kai-lan) are good sources of calcium for children who are unable to tolerate milk or dairy products as in Patient 3. Sun exposure with minimum surface exposure (face and hand) for 30 minutes, 2 times per week at 11am is a simple and natural means to prevent vitamin D deficiency rickets in sunlight-abundant tropical

Malaysia.¹¹

Careful evaluation for clinical features of rickets should be done in breastfed infants and toddlers who are picky eaters, on restrictive diets or have poor growth, particularly following the pandemic lockdown with no outdoor sun exposure. Vitamin D supplementation of 400IU/day +/-calcium supplement should be considered in well breastfed infants and toddlers with suboptimal dietary intake or poor growth, especially when there is minimal sun exposure, to prevent nutritional rickets.

CONCLUSION

Breastfed toddlers who are fussy eaters or on selective special diets are at risk of vitamin D and calcium deficiency, especially during this unprecedented movement control order. Early recognition of these at-risk groups, proper dietary counselling and sun exposure advice should be given to prevent nutritional rickets.

LEARNING POINTS

- This case series highlights nutritional rickets to be potentially rising amongst toddlers on prolonged breastfeeding without appropriate complementary feeding during the Covid-19 lockdown period.
- Recognition of at-risk infants and toddlers, proper dietary counselling, and supplementation with vitamin D 400IU/day +/-calcium when there is minimal sun exposure as in a pandemic lockdown, will prevent the development of nutritional rickets.

CONSENT

Written consent has been obtained from the parents of the patients in this case series.

REFERENCES

1. Thandrayena,K., Pettifor J.M. The roles of vitamin D and dietary calcium in nutritional rickets. Bone Reports 2018 8:81–89
2. Thacher TD, Fischer PR, Strand MA, Pettifor JM: Nutritional rickets around the world:causes and future

- directions. *Ann Trop Paediatr* 2006; 26: 1–16.
3. Kovacs CS. Vitamin D in pregnancy and lactation. *Am J Clin Nutr* 2008; 88(suppl):520S– 8S
4. Pettifor, J.M. Calcium and vitamin D metabolism in children in developing countries. *Ann. Nutr. Metab.* 2014; 64 (Suppl. 2): 15–22
5. Lutter CK, Rivera JA. Nutritional status of infants and young children and characteristics of their diets. *J Nutr* 2003;133:2941S–9S
6. Poh BK, Ng BK, Mohd Din SH et al. Nutritional status and dietary intakes of children aged 6 months to 12 years: findings of the Nutrition Survey of Malaysian Children (SEANUTS Malaysia). *British Journal of Nutrition* 2013; 110: S21–S35
7. Munns CF, Simm PJ, Rodda CP, et al. Incidence of vitamin D deficiency rickets among Australian children: an Australian Paediatric Surveillance Unit study. *Med J Aust* 2012; 196: 466–468.
8. Chan CY, Mohamed N, Ima-Nirwana S, Chin KY. Attitude of Asians to Calcium and Vitamin D Rich Foods and Supplements: A Systematic Review. *Sains Malaysiana* 2018; 47(8): 1801–1810.
9. Munns CF, Shaw N., Kiely M et al. Global consensus recommendations on prevention and management of nutritional rickets. *J. Clin. Endocrinol. Metab.* 2016; 101, 394-415.
10. Recommended nutrient intakes for Malaysia. A report of the technical working group on nutritional guidelines. National Coordinating Committee on Food and Nutrition. Ministry of Health Malaysia 2017
11. Hamid Jan JM & Norliyana A. The association between occupational sunlight exposure & monsoon season on serum vitamin D. ILSI Annual Meeting, ST Petersburg, Florida 2016