

Radiation-Induced Meningioma Following Radiotherapy for Pituitary Adenoma: A Case Report

Ellyda MN^a, Win Mar@Salmah J^b

^a Department of Radiology, International Islamic University Malaysia, Kuantan, Pahang, Malaysia.

^b Department of Radiology, School of Medical Sciences, Universiti Sains Malaysia, Kubang Kerian, Kelantan, Malaysia.

ABSTRACT

It is well known that ionizing radiation has an onco-genetic activity and has been implicated in the causation of brain tumors. However, when a new growth appears adjacent to the site of previous tumor, the diagnosis is more toward recurrence. In addition to that, the possible cause might be overlooked, when it occurs many years after radiation treatment. We report a case of radiation-induced meningioma developed 20 years after the patient received radiotherapy for pituitary adenoma.

KEYWORDS: Ionizing radiation, radiotherapy, oncogene, meningioma, pituitary adenoma.

INTRODUCTION

The development of radiation-induced brain tumor is a feared complication of conventional external-beam radiotherapy even though it is effective in achieving control of tumor growth and hormonal hypersecretion in patients with pituitary adenoma. Radiation-induced tumor is an uncommon but known complication after therapeutic cranial irradiation for acute lymphoblastic leukaemia, intracranial tumors and tinea capitis.^{1,2} Relationships between radiotherapy and subsequent intracranial tumors have been conclusively established³ and meningioma is the most common brain tumor arising consequent to radiation exposure in a previously irradiated field.⁴ To our knowledge, this is the first reported case of radiation-induced meningioma in Malaysia.

CASE REPORT

A 40-year-old lady, presented with several weeks of frequent episodes of dizziness, dropping of left eyelid and double vision of the left eye. She had a past medical history of pituitary macroadenoma with ACTH dependent Cushing's syndrome and underwent transphenoidal excision of the tumor in 1986, followed by external-beam radiotherapy. She was doing well prior to the current admission. Physical examination revealed a middle-aged woman with presence of dorsal hump, truncal obesity, purple striae and proximal

muscle weakness. These findings were consistent with features of Cushing's syndrome. Eye examination showed left periorbital puffiness and left diplopia. She also had a complete left eye ptosis and inability of her left eye to look laterally. Her left pupil was dilated and slightly less reactive to light, however her visual fields were intact. These findings were consistent with oculomotor (CN III) and abducens (CN VI) nerve palsies. The remainder of her cranial nerve (CN) examination was normal. The blood investigations showed hypercortisolemia.

MRI brain revealed a new mass at the left cavernous sinus with no evidence of recurrence tumor in the pituitary fossa. The imaging characteristics of this new mass were most consistent with meningioma. She underwent an excision of the tumor. Intraoperative findings revealed the tumor was arising from greater wing of the left sphenoid bone and had infiltrated into the left part of the cavernous sinus (Figure 1-2). The Histopathological result confirmed the diagnosis of meningioma. CECT abdomen was done to investigate for Cushing's syndrome and revealed bulky left adrenal gland with small nodules within (Figure 3).

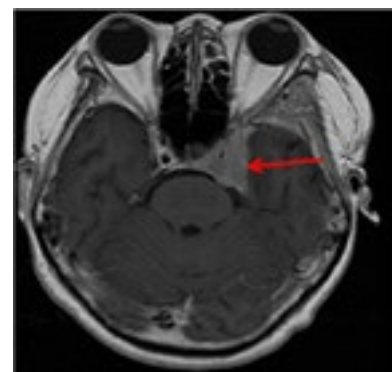


Figure 1. Axial T1 weighted magnetic resonance image with gadolinium enhancement demonstrating an inhomogeneous mass in the left side of the cavernous sinus (red arrow).

Corresponding author:

Dr Ellyda Muhammed Nordin,
Radiology Department,
International Islamic University Malaysia,
Jalan Hospital, 25100 Kuantan,
Pahang Darul Makmur, Malaysia.
Phone: +6095572056,
Fax: +6095149396,
E-mail: elly7575@gmail.com

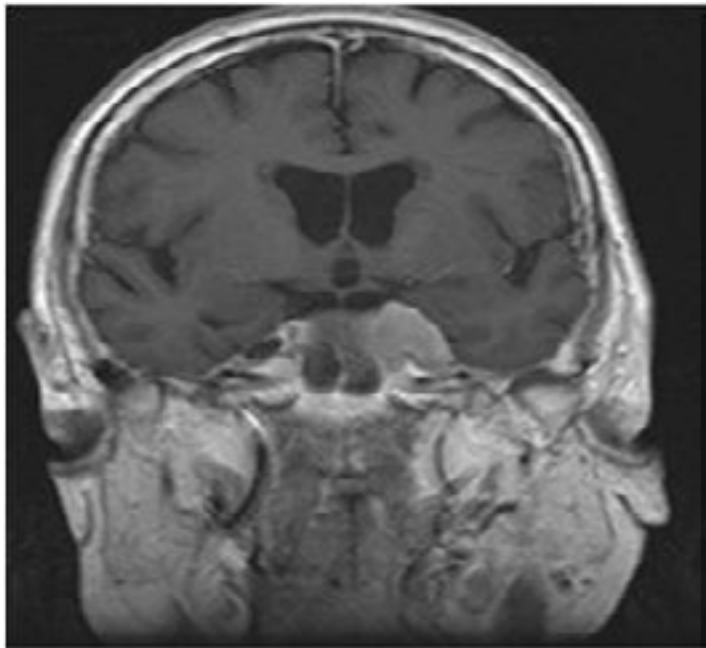


Figure 2. Coronal T1 weighted magnetic resonance image with gadolinium showing that the mass encasing the left carotid artery.

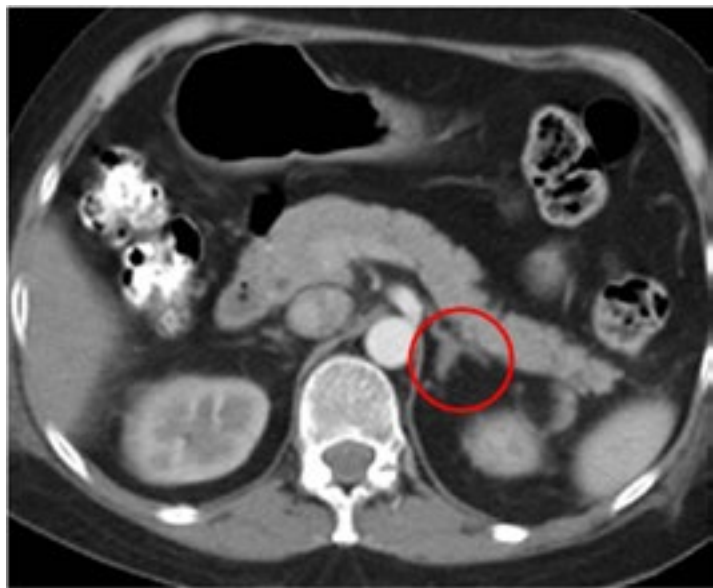

Figure 3. CECT abdomen showed bulky heterogeneously enhancing left adrenal gland with focal hypodensities within, suggestive of left adrenal adenoma.

DISCUSSION

The delayed or long-term side effects of ionizing radiation on neural tissue are known to induce new central nervous system tumors. Earlier published case reports have confirmed the occurrence of radiation-induced brain tumors,^{3,5} in which meningiomas and sarcomas were the most frequent tumors arising consequent to radiation exposure in a previously irradiated field with a latency period of 19-35 years varying with dosage.^{4,6}

Revised Cahan’s criteria for radiation-induced tumors are as follows: (i) must develop in the irradiated area,

(ii) must not present prior to irradiation, (iii) there must be a latent period and (iv) the tumor must be verified histologically and differ histologically from the original tumor that was irradiated.⁶ In the present case, the secondary meningioma satisfied the above mentioned criteria of radiation-induced tumors.

Radiation-induced meningioma has been grouped into three categories by Harrison et al: (i) those due to high-dose (> 20 Gy), (ii) intermediate-dose (10-20 Gy), and (iii) low-dose (< 10 Gy) radiation.⁷ Meanwhile the mean latency from irradiation to

diagnosis of the meningioma was 19 years with a tendency for shorter latency observed in patients treated with higher doses and those who had undergone radiotherapy at younger ages.⁴

A cumulative risk of developing a second brain tumor in patients with pituitary adenoma treated with surgery and radiotherapy has been reported by recent researchers. The risk was 2.0% at 10 years and 2.4% at 20 years after treatment, with a relative risk compared with the normal population of 10.5. Tumors were diagnosed 6-34 years after radiotherapy, with a mean of 6.7 years for astrocytoma and 20.8 years for meningeal tumours.⁸

The location of the radiation-induced meningioma was primarily related to the site of exposure. Calvarial meningiomas were seen in patients treated for tinea capitis whereas skull base meningiomas were found in 4-19% of patients in whom there was a history of high-dose irradiation for primary brain tumors.^{2,9}

The induced type meningioma also had different epidemiological and clinical-pathological profiles from those of spontaneous meningioma. They typically display female preponderance with lower mean age and found adjacent to the focus of irradiation, which was close to the primary lesion^{1,10} as presented in this case.

The treatment of choice for most cases of radiation-induced meningioma is a surgical removal, even though the chances of complete and safe resection may not be possible due to the lesion's frequent multiplicity, aggressive nature, involvement of osseous structures and vessels. In addition, stereotactic radiosurgery or fractionated stereotactic radiosurgery is recognized as another alternative to surgery in some patients, despite their radiation-related origins of tumor.⁹

CONCLUSION

Although radiation-induced meningioma is uncommon; the risk should be taken into consideration whenever decisions are made to use high-dose radiation for the treatment of benign tumors, particularly during childhood, adolescence and young adulthood. Clinicians also must be aware of secondary tumor when managing patients with pituitary tumor, especially when patients presented with new or recurring symptoms after underwent standard radiation therapy.

REFERENCES

1. Sadetzki S, Flint-Richter P, Ben-Tal T, Nass D. Radiation-induced meningioma: a descriptive study of 253 cases. *J Neurosurg* 2002; 97:1078-82.
2. Neglia JP, Meadows AT, Robison LL, et al. Second neoplasms after acute lymphoblastic leukemia in childhood. *N Engl J Med* 1991; 325:1330-6.
3. Kranzinger M, Jones N, Rittinger O, et al. Malignant gliomas as a secondary malignant neoplasm after radiation therapy for craniopharyngioma: Report of a case and review of literature. *Onkologie* 2001; 24:66-72.
4. Al-Mefty O, Kersh JE, Routh A, Smith RR. The long term effects of radiation therapy for benign brain tumors in adults. *J Neurosurg* 1990; 73:502-12.
5. Salvati M, Puzzilli F, Bristot R, Cervoni L. Post radiation gliomas. *Tumor* 1994; 80:220-3.
6. Salvati M, Frati A, Russo N, et al. Radiation induced gliomas: Report of 10 cases and review of literature. *Surg Neurol* 2003; 60:60-7.
7. Harrison MJ, Wolfe DE, Lau TS, Mitnick RJ, Sachdev VP. Radiation-induced meningiomas: experience at the Mount Sinai Hospital and review of the literature. *J Neurosurg* 1991; 75:564-74.
8. Minniti G, Traish D, Ashley S, Gonsalves A, Brada M. Risk of second brain tumor after conservative surgery and radiotherapy for pituitary adenoma: update after an additional 10 years. *J Clin Endocrinol Metab* 2005; 90:800-4.
9. Umansky F, Shoshan Y, Rosenthal G, Fraifeld S, Spektor S. Radiation-Induced Meningioma. *Neurosurg Focus* 2008; 24:E7. *Neurosurg Focus* 2008; 24:E7. doi: 10.3171/FOC/2008/24/5/E7.
10. Strojjan P, Popovic M, Jereb B. Secondary intracranial meningiomas after high-dose cranial irradiation: report of five cases and review of the literature. *Int J Radiat Oncol Biol Phys* 2004; 8:65-73.