

# Enucleation of Extraconal Frontomucocele: A Tripple-Window Approach

Irfan M<sup>a</sup>, Dinsuhaimi S<sup>a</sup>, Roselinda AR<sup>b</sup>, Rani AS<sup>b</sup>

<sup>a</sup> Department of Otorhinolaryngology-Head & Neck Surgery , Universiti Sains Malaysia

<sup>b</sup> Oromaxillofacial Unit , Universiti Sains Malaysia

## ABSTRACT

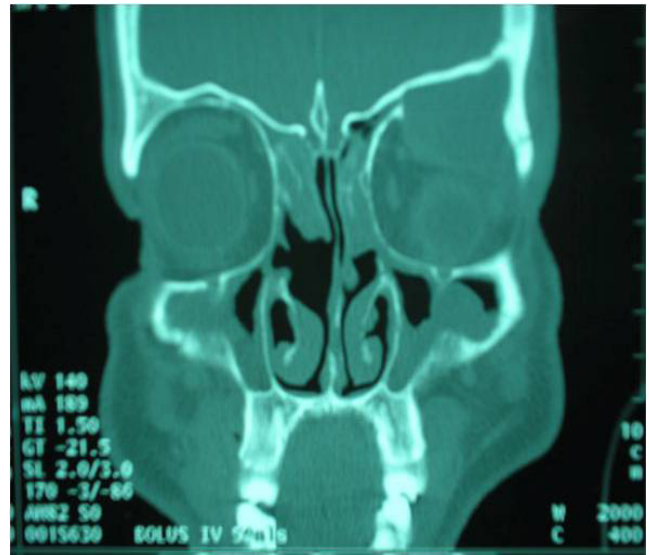Mucoceles are expansile masses originating in the sinuses. They are relatively unusual, occurring most frequently at fronto-ethmoidal region. They are locally destructive. This expansile lesion caused bony erosion and displaces the adjacent structures. We report a case of a patient who presented to our clinic with bulging of his left eye and worsening of the left vision. This was preceded by history of sport injury to his left supraorbital ridge. CT scan revealed that there was an extraconal lesion at the superolateral part of the left orbital cavity which pushed the orbit inferomedially, which consistent with left frontomucocele. He underwent enucleation of the lesion via 3 windows created namely at the left supraorbital ridge, anterior table of left frontal sinus and through the septum separating the frontal sinuses.

## CASE SUMMARY

A 46 year-old Malay male presented to maxillofacial clinic with bulging of his left eye, associated with discharging lesion over the left eyebrow and worsening of his left vision for the past 10 months. He had involved in a sport injury 6 years ago whereby he sustained a fracture at his left supraorbital ridge. Following that, he was subjected for open reduction and internal fixation of the fracture part.

He was doing well until 2 years ago when he went to a private practitioner for the removal of plates due to discomfort sensation over the eyebrow. Later, he noted that his left eyeball was pushed down inferomedially. He also noted of double vision on lateral gaze. Apart from that there was a discharging lesion over the lateral aspect of the left eyebrow.

Computed tomograph (CT) scan revealed an extraconal lesion at the superolateral part of the left orbital cavity which pushed the orbit inferomedially (Figure 1). The mass was in continuity with the left frontal sinus mass through the defect in the superior orbital wall. There was also underlying pansinusitis with polyps in the middle meatus, maxillary antrum, ethmoids and frontal sinuses. He was offered surgical removal of the left frontomucocele.



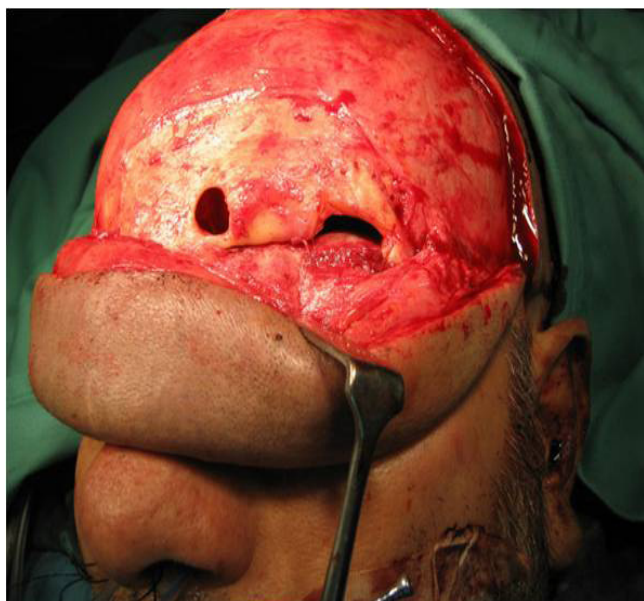
**Figure 1.** Computed tomograph (CT) scan revealed an extraconal lesion at the superolateral part of the left orbital cavity.

Intraoperatively, a bicoronal incision was made and flap rose anteriorly. There was a cystic-like mass at the lateral part of the orbital ridge. As only the anterior part of the mass was visualized, a better exposure was needed. The 1 x 2 cm window (1st window) was created at the lateral part of the left supraorbital ridge. The cystic-like mass was removed and noted that there was a continuation of the orbital cavity with the frontal sinus. After passing the scope medially, there were multiple polyps noted in the left frontal sinus. Orbital wall reconstruction was not done.

A second window was then created at the anterior table of the left frontal sinus in order to give a better exposure to the inside sinus cavity (Figure 2). All visualized polyps were removed with microdebrider and the sinus mucosa lining was curetted. The sinus cavity was left unobliterated. The opposite right frontal

sinus was reached by breaking the septum that separates the two sinuses (third window). All polypoidal mucosa in the right frontal sinus were cleared. No cavity obliteration was done.

Following that, endoscopic sinus surgery was performed in order to clear the osteomeatal complexes. The opening of the frontonasal duct was traced by anterogradely flushing saline into the frontal sinus from the second window. A tube stent was placed in inverted U shaped connecting both right and left frontonasal duct with the ends were outside the nasal cavity. During one year follow-up, the patient was asymptomatic. Diplopia resolved. Clinically there was



no residual or recurrence of the disease. However, polypoidal mucosa was seen in both middle meatuses. Repeat CT scan was not done.

## DISCUSSION

Mucoceles are expansile masses originating in the sinuses. They are relatively unusual, occurring most frequently at fronto-ethmoidal region. They are locally destructive and the erosion and expansion of the bony wall encroach upon and displace the adjacent structures.<sup>1</sup> In general, the patient usually present with frontal headache, nasal obstruction and eye signs such as globe displacement, diplopia, proptosis, lid swelling, palpable mass and at times reduced vision and ptosis. In this patient, he presented more with eye signs (diplopia, ptosis and proptosis) due to the location of the mucocele that was situated at the superolateral to the orbit, that caused the orbit to be displaced inferomedially.

Scarring of the sinus opening is the most common cause for the formation of the mucocele.<sup>2</sup> The frontal and ethmoidal sinuses were the most commonly involved, which reflects the predisposition for their small sinus openings to be damaged during sinus surgery, trauma or by repeated infections with subsequent obstruction and mucocele formation. The majority of paranasal sinus mucoceles occur in the frontal sinus (60%), followed by the ethmoid sinus (30%). Only 10% are lo-

calized in the maxillary sinuses, and they are rarely localized to the sphenoid sinus.<sup>3</sup>

The best modalities of imaging to demonstrate mucocele is a computed tomograph scan. Although frontal sinus mucocele can be readily diagnosed with plain x-rays, maxillary and sphenoid as well as ethmoid originated mucoceles can be missed.<sup>3</sup> Furthermore, in this patient, he had sustained a supraorbital ridge fracture in which plating was done and history of recurrent infection over the fracture site. All of these can lead to artifacts in the plain x-ray and might masquerade the real outline and appearance of the mucocele.

The classical appearance of a frontal sinus mucocele on CT or plain X-ray is that of an opaque, expanded sinus with loss of the normal scalloped margin of the sinus margin. Other changes include depression or erosion of the supraorbital ridge (as demonstrated in this patient scan) and extension of the soft tissue mass across the mid-line through the septum to the opposite frontal sinus.<sup>3</sup> Coincidentally, besides the frontomucocele, we also noted that there were multiple ethmoidal polyps and maxillary antral mucosal thickening that might be one of the contributing factors of the frontonasal duct blockage and worsen the frontal sinus ventilation and drainage, leading to sinusitis.

Endoscopic management of mucoceles protruding into the other sinuses or nasal cavity has been the accepted treatment for years.<sup>2</sup> However, mucoceles presenting with a significant bony separation from the other sinuses or nasal cavity are more complex and difficult to manage. This bony divide needs to be removed by a drill so that a large enough opening is created into the mucocele that will stay patent in the long term. The alternative to drilling away this bone is to approach the mucocele via external incisions, remove its entire lining and obliterate it with fat. However, if the mucocele has eroded the orbital roof or skull base and there is extensive apposition of mucocele mucosa on the orbital periosteum or dura, complete removal of the mucosa is very difficult. Although it is documented that Modified Endoscopic Lothrop Procedure (MELP) is one of the alternative for frontal sinus mucocele enucleation, it is not possible in this case unless to be combined with external approach to reach the superolateral part of the orbit.<sup>2</sup> Considering the site of the mucocele in this patient and the extent that it already go, the purely endoscopic approach is not possible and thus need for the external incision is there.

This patient was subjected for enucleation of the mucocele via bicoronal approach. The anterior part of the mucocele was situated at the superolateral part of the orbit. There was a tract connecting the cyst to the outside which open at the lateral most part of the eyebrow. In view of difficult access to remove the cyst in total, a window was created at the lateral part of the supraorbital ridge. By using Gigli saw, 1 x 2 cm bone was removed in beveled angle. The floor of the left frontal sinus was dehiscent, most probably due to the erosion of the mucocele. Upon tracing medially with the 0° endoscope, we noted that there was polypoidal mucosa in the left frontal sinus. The second window was created at the anterior table of the left frontal sinus. The polyps and polypoidal mucosa were removed by using the microdebrider and curette under endoscopic guide. Later on the third window was created in order to reach the opposite right frontal sinus. Polypoidal mucosa cleared and finally a stent was placed connecting the right and left frontonasal ducts via tranfrontal sinus septum window in the inverted U shape. The two ends were exteriorized at the anterior nares. The stent was kept for six weeks to provide good ventilation to the sinuses while healing took place.

In conclusion, frontomucocele is comparativey a rare lesion with regards to the paranasal sinuses pathology. Depending on the presentation, the site, size and nature of the disease can be very different and the treatment also will be very much individualized. This case demonstrates to us one of the individualized approaches to achieve total enucleation of the mass.

## REFERENCES

1. Lloyd G, Lund VJ, Savy L, Howard D. Radiology in focus: Optimum imaging for mucoceles. *J Laryngol Otol* 2000; 114:233-6
2. Khong JJ, Malhorta R, Selva D, Wormald PJ. Efficacy of endoscopic sinus surgery for paranasal sinus mucocele including modified endoscopic Lothrop procedure for frontal sinus mucocele. *J Laryngol Otol* 2004; 118: 352-6
3. Varghese L, John M, Kurein M. Bilateral asymmetric mucoceles of the paranasal sinuses: A first case report. *Ear Nose Throat J* 2004; 83:834-5
4. Kountakis S. Case of the Quarter Endoscopic Modified Lothrop. *American Rhinologic Society* 2003 [Online]. Available at <http://www.american-rhinologic.org/news.0303.lothrop.phtml>. Accessed 28 January 2009.

