

Stage Protocol in the Management of Infection Following Plating of the Tibia

Nazri MY^a, AS Halim^b

^a*Department of Orthopaedics, Traumatology and Rehabilitation, Kulliyah of Medicine, International Islamic University Malaysia, Kuantan*

^b*Reconstructive Sciences Unit, School of Medicine, Universiti Sains Malaysia, Kubang Kerian, Kelantan, Malaysia*

ABSTRACT

INTRODUCTION: Anterior border of the tibia is covered only by a thin layer of protective tissue. Plating of the tibia often results in wound complication and infection if the injury to this area is not recognized. We review our results of managing infection following plating of the tibia using a protocol base on the status of bone healing and the presence of bone or soft-tissue defect. **Methods:** Eight cases of infection following plating of the tibia were managed according to stage procedures protocols and classification, which is based on the state of bony union and the defect following wound debridement. The soft-tissue defects were managed with local flaps, and the bone defects were managed with Ilizarov bone transport. **Results:** Three patients had more than one bacterium isolated. Gram negative organisms were isolated from seven patients. Methicilline-resistant *Staphylococcus aureus* was isolated in two patients. All patients achieved union with a mean union time of seven months. The infections were controlled in seven patients. One patient had minimal sinus discharge but refused further treatment. **Conclusions:** The stage protocol for the management of infection following plating of the tibia is practical and produces excellent results.

KEYWORDS: Infection, fracture fixation, tibial plating

INTRODUCTION

Tibial fractures often cause damage to the thin protective soft tissue on its anterior surface. Failure to recognize this injury often resulted in post operative wound complication and infection.¹ The incidence of infection after plating of the tibia has been reported as high as 10%.² Aggressive debridement of all necrotic bones and soft tissue is crucial to ensure control of infection. The management of infection would therefore include managing the defect resulted from the wound debridement. We present our experience in managing infection following plating base on the status of bone union and the presence of bone and soft-tissue defect as describe by Ueng and Shih.³

MATERIALS AND METHODS

Between 2003 until 2011, eight cases of infection following plating of the tibia were treated in the

Advance Trauma and Limb Reconstruction Unit, Hospital Tengku Ampuan Afzan, Kuantan. Hospital Tengku Ampuan Afzan is a referral center for Orthopaedic cases in the state of Pahang that has one million populations. It is also a teaching hospital for International Islamic University of Malaysia. The patients were classified base on Ueng³ and Cierny Mader⁴ classification (Table I).

The management of the patient with infected plate depends on the stage of bone union and presence of bone or soft-tissue defect. The treatment algorithm is shown in Figure I. The surgery is done in stages. The first stage is a surgical debridement. The plate is removed if it is found to be unstable during the operation.

The bone and tissue samples are sent for microbiology and antibiotic sensitivity during the surgery. The wound is then temporarily managed by wet saline dressing. A second debridement is done if there is a persistent infection. The plate is removed regardless of the stability during the second debridement. The bone is then stabilized by an external fixation device.

Corresponding author:
Dr Nazri Mohd Yusof
Associate Professor
Department of Orthopaedic, Traumatology and Rehabilitation
International Islamic University of Malaysia
Jalan Hospital, 25150 Kuantan, Pahang
Telephone number: 06019 9984086
Fax number: 0609 5144451
E mail: nazrimy2000@yahoo.com

Table 1.(a) Classification of infected fractures modified from Ueng *et al.*

Type

- I United fracture
- II Ununited fracture

Class

- A No significant bone loss or soft tissue defect
- B Large soft tissue defect require soft tissue reconstruction (flap)
- C Large bone defect require bone reconstruction (bone graft, bone transport or shortening)
- D Large soft tissue and bone defect require reconstruction

(b) Classification of osteomyelitis by Cierny and Mader

Anatomic type

- I Medullary
- II Superficial
- III Localize
- IV Diffuse

Physiological class

- A Good immune system and delivery
- B Compromised locally (B^L) or systemically (B^S)

Figures

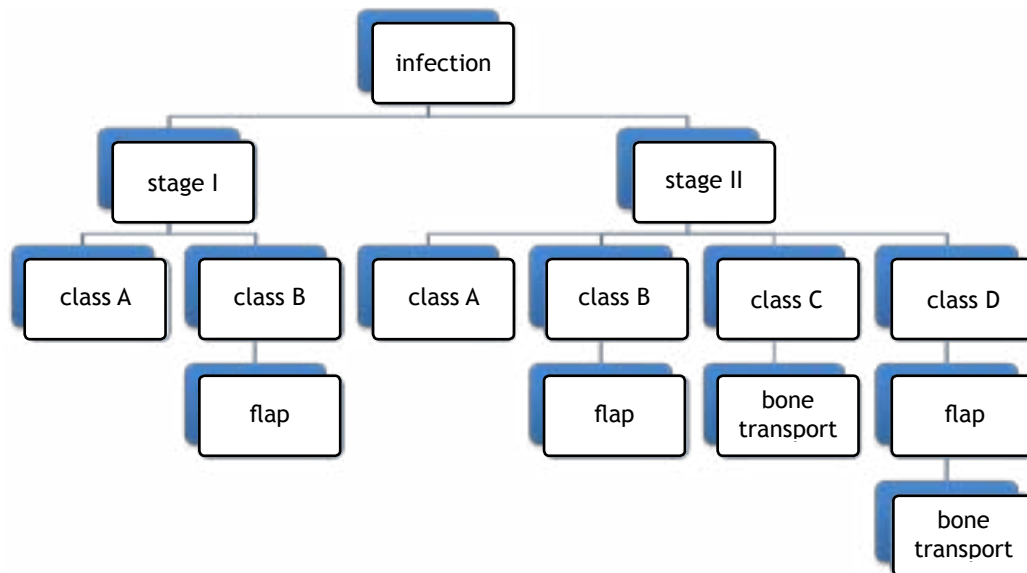


Figure I. Treatment algorithm for infection following plating according to classification by Ueng *et al*

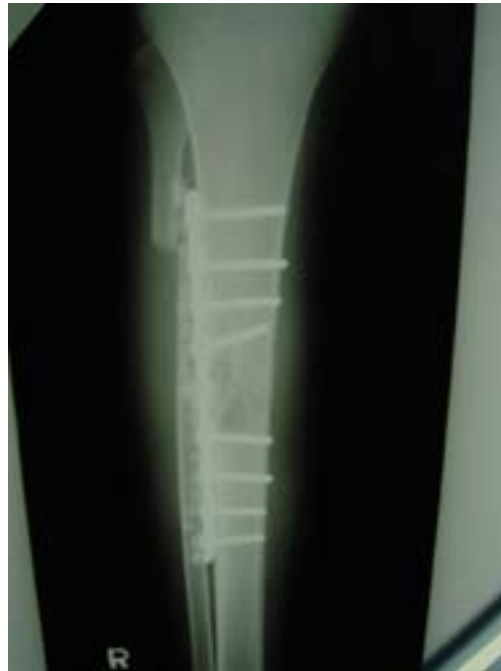

Figure II. Plain radiograph showing plate at the lateral border of the tibia with antibiotic beads

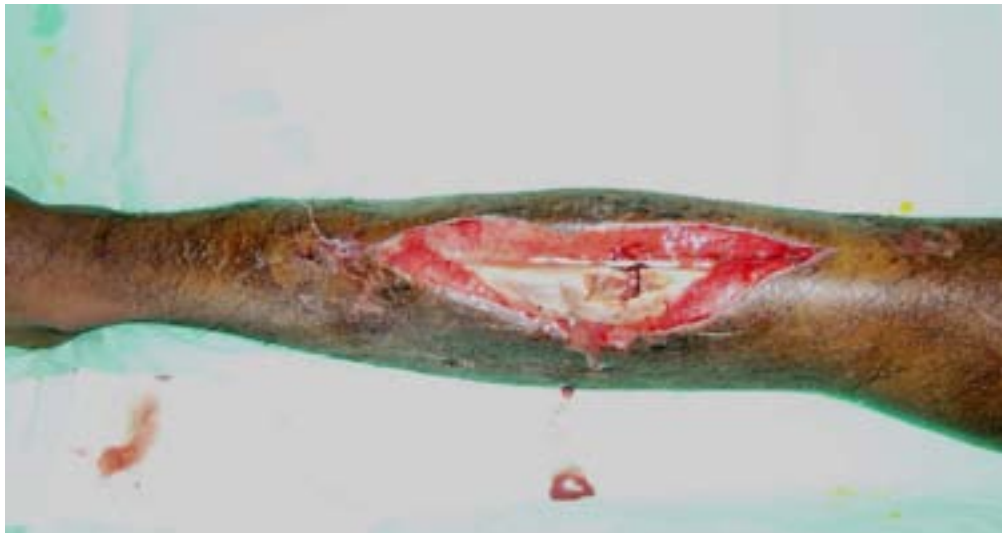

Figure III. Clinical photograph of infection with an exposed bone and metal implant

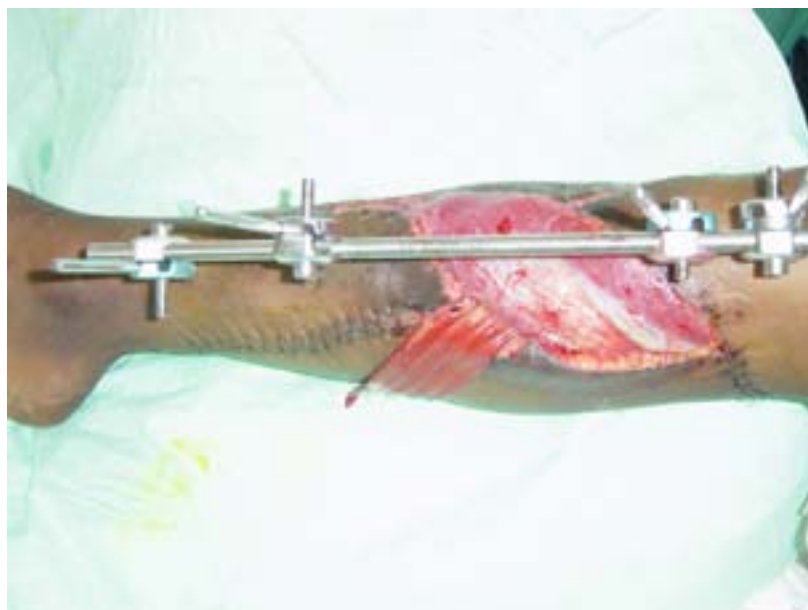

Figure IV. Clinical photograph following wound closure with gastrocnemius muscle flap

The next stage depends on the class of the infection. In class A (no bone and soft-tissue defect), the fracture will usually unite without additional surgery. In class B (soft-tissue tissue defect), the exposed bone is covered by a local flap. In class C (bone defect), the bone gap is bridged using bone transport. In class D (soft-tissue and bone defect), the surgery is done in stages. The second stage is wound coverage by a flap followed by bone transport using the Ilizarov circular ring fixator after the wound has healed.^{3,5}

Intravenous antibiotic is given for two weeks and continue with oral antibiotic for another four weeks according to the sensitivity result. Local antibiotic bead (Septopal) or Tobramycin calcium sulphate pallet is use to fill in the dead space left after the debridement in two of the patient. The antibiotic beads are removed after 6 weeks. Tobramycin calcium sulphate pallet does not require surgical removal.

RESULTS

The mean age of patients was 29 years old (range 16 to 53). Five patients had closed fractures following motor-vehicle accident with one complicated by compartment syndrome, and the other had an open fracture. One patient had diabetes mellitus, and another had been positive for HIV and Hepatitis B and C.

In three patients (patient 1, 3 and 8), the plates were retained and the wounds were closed with local antibiotic beads. All of them (with retained implant) had persistent infection that leads to wound breakdown. In one patient (patient 7), the wound was left open for drainage. A split thickness skin graft was done after the infection was controlled. Otherwise, the plate was removed during the first debridement in the rest of the patients.

Table II. Characteristic and outcome of patients with infection following plating of tibia

No.	Age	Onset of infection	Wound size (cm)	CM	Ueng	No. of debridement	Soft tissue reconstruction	Bone reconstruction	Culture result	Union time (month)	Infection at last follow up
1	18	Early	10 X 5	IVA	IIB	4	gastrocnemius flap	None	<i>enterobacter gergoviae, pseudomonas sp.</i>	6	Resolved
2	16	delayed	2X10	IVA	IIB	2	medial gastrocnemius myocutaneous flap	None	<i>pseudomonas aeroginosa</i>	12	Resolved
3	53	delayed	3X4	IVB	IID	3	lateral gastrocnemius myocutaneous flap	ilizarov bone transport	<i>E coli.</i>	12	resolved
4	19	early	2X6	IVA	IIB	2	gastrocnemius myocutaneous flap	none	<i>klebsiella ozaenae Pseudomonas aeroginosa,</i>	7	persistent
5	40	Late	2X4	IIIB	IB	3	Gastrocnemius flap	None	<i>enterobacter cloaca</i>	5	Resolved
6	21	Delayed	None	IVA	IIC	1	None	Ilizarov bone transport	<i>Enterobacter aeroginosa</i>	5	Resolved
7	29	Early	None	IVA	IIA	1	Skin graft	None	<i>MRSA</i>	4	Resolved
8	36	early	2X2	IVA	IID	3	Fasciocutaneous flap	Ilizarov bone transport	<i>MRSA, acinobacter baumanii</i>	6	resolved

OA-OTA - Orthopaedic Trauma Association fracture classification, Early < 2 weeks, delayed > 2 weeks¹³, CM-Cierny Mader classification

The average number of wound debridement is 2.4 (range from 1 to 4). Four patients had persistent infection after the local flap surgery. The first patient (patient 1) with gastrocnemius muscle flap had persistent infection and wound breakdown within a week of surgery. He underwent a repeated debridement followed by fasciocutaneous flap to cover the wound. In one patient (patient 3) with Cierny Mader's type IVB, intercalary resection was done after he developed recurrence three months after the flap surgery. He underwent bone transport procedure to fill the bone gap following resection. The third patient (patient 4) developed sinus discharge one month after wound closure but refused a further surgical procedure. The last patient had persistent infection after insertion of Tobramycin calcium sulphate pallet. The infection was controlled after removal of plate and intercalary resection of the infected bone. Three patients had polymicrobial infections. Gram negative organism was isolated in seven patients. *Pseudomonas aeruginosa* and Methicilline resistant staphylococcus aureus were isolated in two patients.

All patients achieved union at the end of follow up. The mean union time was seven months (ranges from 4 to 12 months) after the injury. At the end of follow up, only one patient had persistent infection (patient 4) but able to ambulate normally following fracture union. The summary of the patients' data is shown in Table II.

DISCUSSION

Our result showed that most of the infections were caused by gram-negative organisms. Although infection following internal fixation was most commonly caused by *Staphylococcus aureus*; the incidence of gram-negative infection is increasing. Our studies showed that the gram-negative infection has increased from 19 percent in 2004 to 60 percent in 2006.^{6,7} Gram negative infections have been associated with a poorer outcome. Tice *et al.* noted that *Pseudomonas aeruginosa* infection was associated with more than a two-fold increase in recurrence as compared to infection cause by *Staphylococcus aureus*. They also noted that *Pseudomonas* infection carries a higher risk of amputation. They suggested prolonging the antibiotic or using a more intense combination antibiotic therapy for this type of infection.⁸

Our result also showed that all the infections were caused by highly virulence organism regardless of the onset of symptoms. Trampuz and Zimmerli classified infection associated with fracture fixation devices as early and delayed. Early infections were caused predominantly by highly virulence organism while delayed infections were caused by low virulence organism.⁹

Host factors do influence the ability to resist infection and the wound healing.⁴ However, in two

of our patients with physiology class B host, the infections were able to be controlled with multiple debridements. The patient who had persistent infection was a healthy young man (class A host) who refused additional surgery.

Antibiotic therapy, without removal of implant has been successful in treating a patient with low grade infection (no sinus discharge, stable implant and good surrounding soft tissue) with symptoms of less than one year.¹⁰ A more severe infection requires removal of implant and debridement of necrotic tissue to control the infection. The use of local antibiotic beads without removal of implant also has been done with variable success.¹¹ However, it was not successful in our patient. Our entire patients required removal of implant to achieve control of infection. This could be due to the microorganisms growing in biofilm that is protected from the antibiotics and host immune response.¹² The only way to remove the biofilm is to remove the implant from the patient.

All of our patients had multiple surgeries before the infection was controlled, and union time was delayed. Ueng and Shih reviewed 23 patients with infected tibial plate osteosynthesis. They noted that the number of surgical procedures, and the time of the union was related to the bone defect that is present following debridement.³

Treatment using Ilizarov fixator that simultaneously reconstruct the bone and the soft tissue using the open wound technique has been performed with good results.¹³ However, a stage procedure of soft-tissue reconstruction using flaps, followed by bone reconstruction has gained more acceptances.^{3,5}

Three of our patient undergone Ilizarov bone transport to reconstruct bone defect following debridement. One patient developed pin-tract infection that required removal of the frame. He had poor social support and also developed depression and required psychiatric treatment. Dendinos was able to eradicate the infection in all of their 28 patients of tibial osteomyelitis treated with Ilizarov bone transport.¹³ All, except one patient developed non-union and opted for amputation. They also noted that Ilizarov bone transport was associated with many complications like pain, aedema, refracture, depression and pin-tract infection. The other option for restoring bone defect is bone grafting. Ueng noted that the risk of recurrence of infection and stress fracture was higher in bone grafting group.³

We found that staged procedure resulted in better wound care and provides durable soft-tissue cover during the bone reconstruction procedure. However, the stage procedure requires multiple surgeries and prolongs intensive treatment. The procedure may not be acceptable to a patient who has a minimal functional deficit. In one of our patients, he prefers not to undergo radical resection and bone transport with a circular external fixator to remove the

infection. This phenomenon has also been reported by Shiha *et al.*, who noted that the acceptance and the compliance are poor in a patient who underwent a reconstructive procedure with the Ilizarov fixator.¹⁴

CONCLUSIONS

The treatment for infection following plating of the tibia using a staged protocol proves to be effective in achieving union in all patients with low rate of persistent infection.

REFERENCES

1. Heppert V, Rheinwalt K, Winkler H, Wentzensen A. Infection of the proximal tibia after fractures- An avoidable complication. *Eur J Orthop Surg Traumatol* 1997;7:195-8.
2. Johner R, Wruhs O. Classification of tibial shaft fractures and correlation with results after rigid internal fixation. *Clin Orthop* 1983;178:7-25.
3. Ueng WN, Shih CH. Management of infected tibial plate osteosynthesis using a staging system for infected fractures. *J Formos Med Assoc* 1992;91:531-7.
4. Cierny G, Mader JT. A clinical staging system for adult osteomyelitis. *Clin Orthop* 2003;414:7-24.
5. Patzakis MJ, Zalavras CG. Chronic posttraumatic osteomyelitis and infected nonunion of the tibia: Current management concepts. *J Am Acad Orthop Surg* 2005;13:417-27.
6. Nazri MY, Halim YA. Outcome of infection following internal fixation of closed fractures. *Med J Malaysia* 2004;59:665-69.
7. Yusof NM, Zulkifly A, Khalid KA, et al. Infection following internal fixation of closed fractures. *International Medical Journal Malaysia* 2006;5(1).
8. Tice AD, Hoaglund PA, Shoultz DA. Risk factors and treatment outcome in osteomyelitis. *J Antimicrob Chemother* 2003;51:1261-8.
9. Trampuz A, Zimmerli W. Diagnosis and treatment of infections associated with fracture fixation devices. *Injury* 2006;37:S59-66.
10. Zimmerli W, Widmer AF, Blatter M, Frei R, Ochcner PE. Role of Rifampin for the treatment of orthopaedic implant-related Staphylococcal infections. A randomized controlled trial. *JAMA* 1998;279:1537-41.
11. Klemm K. The use of antibiotic-containing bead chains in the treatment of chronic bone infection. *Clin Microbiol Infect* 2001;7:28-31.
12. Costerton JW. Biofilm theory can guide the treatment of device-related orthopaedic infections. *Clin Orthop* 2005;437:7-11.
13. Dendrinis GK, Kontos S, Lyritsis S. Use of the Ilizarov technique for treatment of non-union of tibia associated with infection. *J Bone Joint Surg Am* 1995;77:835-46.
14. Shiha A, El-Deen MA, Khalifa AR, Kenaway M. Ilizarov gradual correction of genu varum deformity in adults. *Acta Orthop Belg* 2009;75:784-91.