

# A Case of Acute Hepatitis E Complicated by Acute Pancreatitis in Eastern India

Rudrajit P, Shubhabrata D, Sourav P, Partha SC, Jayati M, Bhattacharya R

Department of Medicine, Medical College Kolkata, Kolkata, West Bengal, India

## ABSTRACT

Viral hepatitis may be occasionally associated with acute pancreatitis. Usually the patient presents with abdominal pain in the second or third week of illness. Hepatitis A or E viruses are mostly implicated. HEV related acute pancreatitis was first reported only 12 years ago. We report a case of a young male presenting with acute Hepatitis E infection complicated by pancreatitis. He had an uneventful recovery. This is probably the first report of this association from Eastern India.

**KEYWORDS:** Hepatitis E, pancreatitis, abdominal pain, Amylase

## INTRODUCTION

Viral hepatitis may be occasionally associated with complications like cholestasis, arthritis, angioedema, proteinuria, myocarditis and peripheral neuropathy.<sup>1</sup> However, pancreatitis as a complication is rarely reported.<sup>2</sup> Thus clinical suspicion needs to be high in cases of severe abdominal pain in apparent hepatitis and early diagnosis and management of the pancreatitis can prevent mortality. Hepatitis E is endemic in India, and outbreaks occur following flooding and breakdown of sanitation barriers in monsoon.<sup>3</sup> We here report a case of acute pancreatitis secondary to Hepatitis E infection. As far as we could search, this is probably the first report of this association from Eastern India.

## CASE REPORT

A 24-year-old non alcoholic male was admitted with gradually increasing jaundice for ten days. Before admission, he had mild right upper quadrant pain for two days and altered sensorium for one day. There was

no history of fever, arthralgia, myalgia, unprotected sexual exposure or hepatotoxic drug intake. He had no history of liver disease, blood transfusion or gastrointestinal bleeding. He did not have any recent history of travel, but he stayed temporarily in a crowded quarter for unskilled workers.

On examination, there was bilateral subconjunctival hemorrhage. He was delirious with Glasgow coma scale score of 9/15. Plantar response was bilaterally extensor. Soft liver was palpable 3 cm below the right costal margin. He was hemodynamically stable.

Laboratory tests revealed hemoglobin of 15gm/dL with total leukocyte count 34 400/ cmm (neutrophil 93%, lymphocyte 4%) and platelet count 52000/cmm. Red cell indices were normal.

Blood random glucose came as 57 mg/dl (3.17 mmol/L) with urea/creatinine of 65 mg%/1.04 mg% respectively. Liver function tests revealed total bilirubin of 18.5 mg% (direct=11; indirect=7.5); Aspartate aminotransferase (AST)-1485 IU/L, Alanine aminotransferase (ALT)-2810 IU/L (N: 35 for both); alkaline phosphatase- 485 IU/L (N=250); serum albumin 3.2 G%, globulin 3.1 gm%; Prothrombin time 16 seconds (INR-1.4). Viral serology revealed positive anti HEV IgM in high titer (1:512). HBsAg, Anti HCV, Anti HAV IgM were negative.

Corresponding author:

Dr Rudrajit Paul  
15/5 Bose Pukur Road, Kolkata 700 039  
West Bengal, India  
Tel: 91 9433824341  
E-mail: docr89@gmail.com

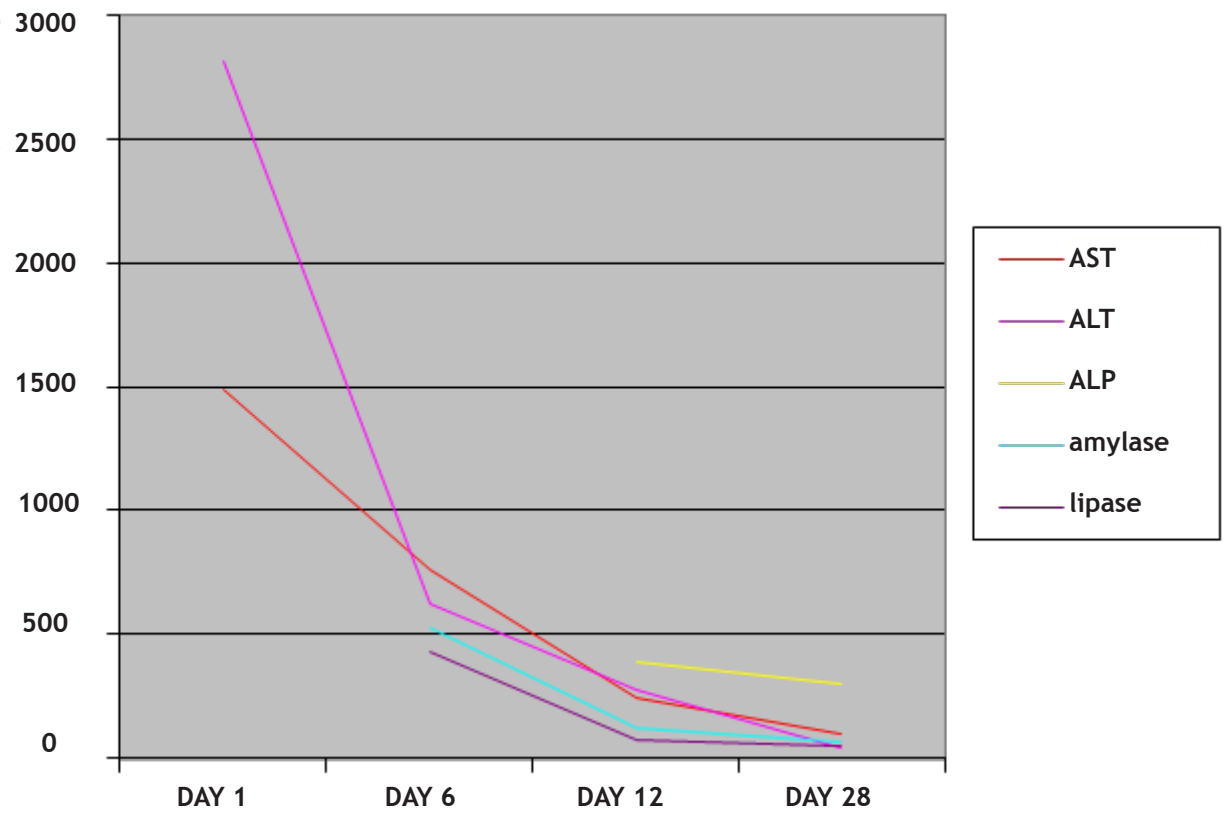


Figure 1. Changes in blood parameters of our patient with time

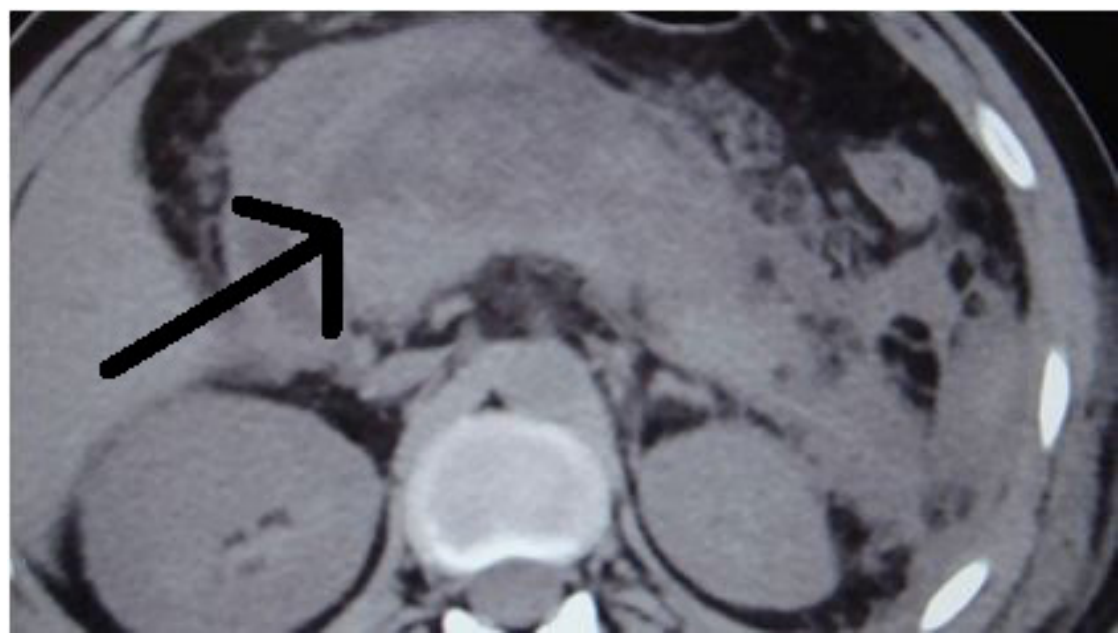


Figure 2. Contrast enhanced CT scan of abdomen of the patient showing edematous pancreas (black arrow) with peripancreatic edema.

The patient was managed conservatively with fluids, lactulose (for hepatic encephalopathy as proved by delirium and low GCS score), gut sterilizing antibiotics like rifaximin and mannitol (to decrease cerebral edema) for initially two days. By the third day, he regained consciousness and his appetite also started to return. However, the right upper quadrant pain was persistent, and he also started to have vomiting from the 6<sup>th</sup> day of admission. Abdomen was diffusely tender and auscultation of the abdomen revealed sluggish bowel sounds. An ultrasonography failed to reach any conclusion due to gas shadow. So we did a Computed Tomographic scan of the abdomen which revealed enlarged edematous pancreas (Figure 2) with some peri pancreatic edema. There was no pancreatic calcification.

Blood tests for amylase /lipase came as 526 IU/L (N<80) and 429 IU/L (N<60) respectively. There was no evidence of gall stones. Blood lipid levels and calcium were normal. PaO<sub>2</sub> was normal. C-reactive protein was 32 g/L (N<6). Magnetic resonance cholangio-pancreatography could not be done due to financial reasons. The patient was again put on intravenous fluids with pancreatic enzyme supplementation to suppress pancreatic secretion. By BISAP scoring, he had only the signs of SIRS, but no other adverse markers. Slowly, his symptoms resolved and after 6 more days, his amylase / lipase levels were 120/78 (both in IU/L) respectively. Blood test for CMV viral serology was negative. In the meantime, his liver function tests had also improved, and SGOT/SGPT levels were 243/280 IU/L respectively. Figure 1 shows the blood test reports in temporal profile of the patient.

Thus the case was diagnosed as acute pancreatitis (moderate grade) secondary to Hepatitis E virus infection.

## DISCUSSION

Association of viral hepatitis with acute pancreatitis is rarely reported.<sup>2</sup> It is mostly associated with hepatitis A or E.<sup>2</sup> It mostly manifests in second to third week of hepatitis illness with abdominal pain and nausea.<sup>2</sup> Pancreatitis due to Hepatitis E virus was first reported in 1999 from New Delhi.<sup>4</sup> Hepatitis A or B viruses were generally more likely to cause pancreatitis.<sup>2</sup> However, in a study from Nepal, they have found 18 out of 25 cases of hepatitis-related pancreatitis caused by Hepatitis E virus (HEV).<sup>5</sup>

The hepatotropic viruses are known to invade the pancreas. Subclinical occult pancreatic involvement is quite common as found in autopsy studies but overt clinical pancreatitis occurs only rarely.<sup>6</sup> The exact mechanism of pancreatitis in hepatitis is not known; proposed theories include direct pancreatic injury, edema of the ampulla of Vater and release of lysosomal enzymes from liver.<sup>5</sup> Also; young males are mostly affected by pancreatitis, although the cause for this gender predisposition is not known.<sup>7</sup>

Abdominal pain is a clinical clue to the possibility of pancreatitis, but other causes like stretching of Glisson's capsule in hepatitis may also contribute to the pain.<sup>7</sup> In a screening study from Jaipur. They found acute pancreatitis in 5.6% of viral hepatitis cases, but among the patients of hepatitis with abdominal pain, 29.2% had pancreatitis.<sup>7</sup> Thus, routine screening for pancreatitis in hepatitis cases may not be justified, but patients presenting with abdominal pain should definitely be investigated. Most of the cases of pancreatitis due to HEV have been reported from Asia. Thus Indian physicians should have a low threshold for investigating a viral hepatitis E complicated by abdominal pain, very low glucose or high leukocyte count.

Sometimes, pancreatitis may be the presenting feature of viral hepatitis and thus, pancreatitis patients also should be followed for development of jaundice.<sup>8</sup>

Usually, pancreatitis in acute viral hepatitis has a benign course.<sup>2,4,5</sup> Unless shock or fulminant hepatic failure is superimposed, the patients have an uneventful recovery. Our patient also recovered on conservative management. However, early diagnosis is required to prevent devastating outcomes. Also, rarely, a relapsing form of pancreatitis may occur after viral hepatitis and thus, follow-up is necessary.<sup>8</sup>

The following table shows the non-hepatic complications of different viral hepatitis<sup>1</sup>: -

**Table 1.** Different non hepatic complications of viral hepatitis

Viral etiology	Nervous system	Non-hepatic gastrointestinal system	Rheumatological system	skin	others
Hepatitis A <sup>9</sup>	--	Pancreatitis, acalculous cholecystitis	Arthritis	Purpura	Hemolysis
Hepatitis B <sup>10</sup>	Peripheral neuropathy, gullain barre syndrome [?]	--	Polyarteritis nodosa, serum sickness	Palpable purpura, popular acrodermatitis of childhood, necrotizing vasculitis	Membranous and membranoproliferative nephropathy, nephrotic syndrome, aplastic anemia
Hepatitis C	Fatigue, neurocognitive dysfunction, transverse myelitis, peripheral neuropathy <sup>11</sup>	---	Arthritis, cerebral vasculitis, cryoglobulinemia, thyroiditis	Lichen planus, lichen myxoedematosus, mooren corneal ulceration, porphyria cutanea tarda	Diabetes mellitus, membranoproliferative glomerulonephritis, membranous nephropathy, thrombocytopenia
Hepatitis E	polyradiculopathy	Pancreatitis	--	--	--

## CONCLUSION

We present this case to highlight this rare complication of HEV infection. This is probably the first report of this association from Eastern India. Since Hepatitis E is very common in India, we should exclude pancreatitis in a viral hepatitis patient presenting with abdominal pain or with a very high leukocyte count.

## REFERENCES

- Dienstag JL. Acute Viral Hepatitis. In: Longo DL, Kasper DL, Jameson JL, Fauci AS, Hauser SL, Loscalzo J, eds. *Harrison's Principles of Internal Medicine*. USA: The McGraw-Hill Companies Inc., 2011:2552-3.
- Bhagat S, Wadhawan M, Sud R, Arora A. Hepatitis viruses causing pancreatitis and hepatitis: a case series and review of literature. *Pancreas* 2008; 36:424-7.
- Hepatitis E. World Health Organization:Global Alert and response [online]. Available at: <http://www.who.int/csr/disease/hepatitis/whocdscsredc200112/en/index4.html#incidence>. Accessed 2012, Aug 6.
- Mishra A, Saigal S, Gupta R, Sarin SK. Acute pancreatitis associated with viral hepatitis: a report of six cases with review of literature. *Am J Gastroenterol* 1999; 94:2292-5.
- Sudhamshu KC, Khadka S, Sharma D, Chataut SP. Acute pancreatitis in acute viral hepatitis. *J Nepal Med Assoc* 2011; 51:7-10.
- Ham JM, Fitzpatrick P. Acute pancreatitis in patients with acute hepatic failure. *Am J Dig Dis* 1973; 18:1079-83.
- Jain P, Nijhawan S, Rai RR, Nepalia S, Mathur A. Acute pancreatitis in acute viral hepatitis. *World J Gastroenterol* 2007; 13:5741-4.
- Borgohain S, Agarwal AK, Dudeja RK, Singla S, Roychowdhury A. Acute pancreatitis associated with acute Hepatitis E virus infection. *Journal Indian Academy of Clinical Medicine* 2000; 1:282-4.
- Willner JJ, Uhl MD, Howard SC, et al. Serious hepatitis A: an analysis of patients hospitalized during an urban epidemic in the United States. *Ann Intern Med* 1998; 128:111-4.
- Shim M, Han SHB. Extrahepatic manifestations of chronic hepatitis B. *Hep B Annual* 2006; 3: 128-54.
- Annunziata P, Marroni M, Francisci D, Stagni G. Acute transverse myelitis and hepatitis C virus. *Infez Med* 2005; 13:45-7.