

An Unusual Cause of Lobulated Lung Mass

Mohamed Faisal AH, Tan HL, Andrea BYL

Respiratory Unit, Department of Medicine, University Kebangsaan Malaysia Medical Centre (UKMMC)

ABSTRACT

Eventration of the diaphragm is caused by weakened musculature of the diaphragm. This can occur in one or both hemidiaphragms. Symptoms may be minimal and it is usually detected incidentally on chest radiograph which would show an elevation of the diaphragm. We report and discuss a case of eventration of right diaphragm in a patient presented with a lobulated lung mass on chest radiograph.

INTRODUCTION

Eventration of the diaphragm is caused by weakened musculature of the diaphragm. This can occur in one or both hemidiaphragms. Symptoms may be minimal and it is usually detected incidentally on chest radiograph which would show an elevation of the diaphragm. Our patient presented atypically with a lobulated lung mass on chest radiograph.

Case Report

A 64-year-old gentleman, an ex-smoker of 5 years, who has hypertension, seropositive rheumatoid arthritis and a history of surgical repair for perforated gastric ulcer and incisional hernia

presented to us with complaints of cough with expectoration for a month. The symptom started during his hajj pilgrimage and persisted despite with one week treatment of amoxicillin/clavulanate and azithromycin. There was no fever, shortness of breath, hemoptysis or constitutional symptoms.

Physical examination revealed that he was afebrile, not tachypnoeic with oxygen saturation 96% on room air. Chest examination revealed decreased chest expansion, dullness on percussion and reduced breath sound on right lower zone.

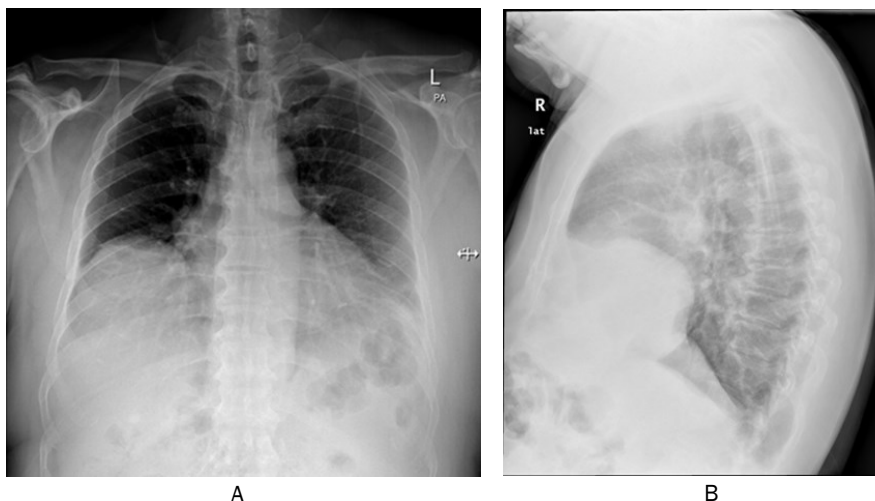


Figure 1: Postero-anterior (A) and lateral view chest x-ray showing homogenous lobulated opacity in right lower zone

Corresponding author:
 Mohamed Faisal Abdul Hamid MBBS(IIUM),
 M.Med (UKM)
 Respiratory Unit, Universiti Kebangsaan
 Malaysia Medical Centre
 email : arabinose@hotmail.com

Chest X-ray (Fig 1A and 1B) showed a well-defined homogenous lobulated opacity in the right lower zone. There was no mass effect or pleural effusion. Further assessment with right lateral view chest x-ray revealed the opacity was located anteriorly with a contour of a diaphragm. Spirometry was normal with forced expiratory volume at 1 second (FEV1) of 1.94L (87% of predicted), forced vital capacity (FVC) of 2.34L (84% of predicted), FEV1/FVC 83%, and peak expiratory flow rate (PEFR) of 334mls (82% of predicted). CT thorax (Fig 2A and 2B) was done and confirmed an elevation of the anteromedial aspect

of right hemidiaphragm with herniation of the superior aspect of liver. There was no lung mass, lung nodule or mediastinal lymphadenopathy. A

diagnosis of eventration of right hemidiaphragm was made and he was given reassurance and follow up appointment in respiratory clinic.

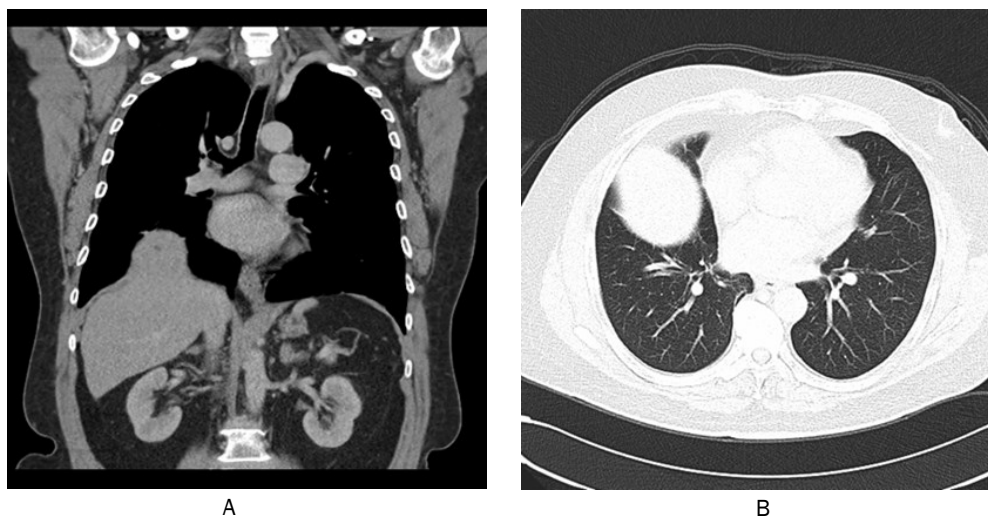


Figure 2: CT thorax coronal view (A) and axial view (B) confirmed an elevation of the anteromedial aspect of right hemidiaphragm with herniation of the liver

DISCUSSION

Diaphragmatic eventration or “Relaxatio diaphragmatica” is a condition where the paralytic/weakened diaphragm is elevated but retains its continuity with the attachment. This causes upward displacement and herniation of the abdominal viscera. This condition rarely occurs on the right side due to the buffering effect of the liver.¹ Diaphragmatic eventration may either be congenital due to developmental defect; or it could be due to traumatic.

Three types of herniation can occur as described by Peck.² Type I involves herniation of the entire liver, type II involves herniation of part of the liver and type III represents type I and II associated with herniation of the other abdominal viscera. As in our case, it would be classified as type II category.

Unilateral diaphragmatic paralysis usually involves phrenic nerve injury by surgical or neoplastic involvement and both the right and left hemidiaphragms are affected equally. In an adult patient, it is postulated that a viral neuritis causing phrenic nerve dysfunction is the more likely cause.³ This is more common in males and involves the right hemidiaphragm.

Spectrum of disease presentation may range from asymptomatic in most cases to life threatening respiratory distress especially in children. Asymptomatic cases are detected incidentally by CXR. In some adults, symptoms occur when intra-abdominal pressure suddenly increases. Symptoms are dyspeptic, respiratory, and cardiac origin. Patients may present with nausea, vomiting, belching, dyspnea, chest

pain, cough, and palpitations. Recurrent chest infections may occur especially in children. Ruptured diaphragmatic eventration may also cause lung collapse giving a false impression of pneumothorax on chest xray.⁴

Diagnosis of diaphragmatic eventration in a resource limited environment can be made by chest radiograph and barium studies. Chest radiograph will show an elevated diaphragm while barium studies will demonstrate barium coated intrathoracic stomach and bowel loops. An associated liver herniation can be demonstrated by liver scan using Tc-99m sulfur colloid which will show a “collar” sign.⁵ In our patient, CT Thorax was sufficient to make the diagnosis.

As with our patient, being an ex-smoker with the presence lobulated mass on the lower lobe of the right lung always raised the suspicion of a lung carcinoma. However further testing showed that the lobulated mass was actually the diaphragmatic eventration with liver herniation. Since his symptoms were minimal, he was treated conservatively, however he should be warned of possible complications such as recurrent chest infections as well as dyspeptic and cough symptoms in the future. If the symptoms progress, thoracoscopic plication of the diaphragms should be offered.

In conclusion, we should consider eventration of the diaphragm as a differential diagnosis of a rounded opacity in the right lower zone. Reviewing serial chest radiographs in the past may be helpful. A CT thorax would confirm the diagnosis.

REFERENCES

1. Poe RH, Schowengerdt CG. Two cases of atraumatic herniation of the liver. *Am Rev Respir Dis* 1972;105(6):959-63.
2. Peck WA. Right-sided diaphragmatic liver hernia following trauma. *Am J Roentgenol Radium Ther Nucl Med* 1957; 78(1):99-108.
3. Stowasser M, Cameron J, Oliver WA. Diaphragmatic paralysis following cervical herpes zoster. *Med J Aust* 1990;153(9):555-6.
4. Servais EL, Stiles BM, Finnerty BM, Paul S. Ruptured diaphragmatic eventration a rare cause of acute postpartum dyspnea. *Ann Thorac Surg* 2012;93(6):143-4.
5. Iochum S, Ludig T, Walter F, Sebbag H, Grosdidier G, Blum AG. Imaging of diaphragmatic injury: a diagnostic challenge? *Radiographics* 2002;22:103-16.