

IJCS

International Journal
of Care Scholars
ISSN: 2600-898X

Nursing Management of Hemodialysis Access Using Subclavian and Femoral Catheters in an ESRD Patient with AV Fistula Contraindications: A Case Report

Mohammed Mutahar Abdullah¹ & Patimah Abdul Wahab^{2*}

¹Faculty of Medicine and Health Sciences, Universitas Muhammadiyah Yogyakarta, Yogyakarta, Indonesia

²Department of Medical Surgical Nursing, Kulliyah of Nursing, International Islamic University Malaysia, Pahang, Malaysia

ABSTRACT

Background: Arteriovenous (AV) fistula is the preferred method for long-term hemodialysis access in end-stage renal disease (ESRD). However, central venous catheters, such as subclavian and femoral lines, are necessary when there are contraindications. This case study aims to describe the nursing management of vascular access in an end-stage renal disease (ESRD) patient with contraindications to arteriovenous (AV) fistula creation, highlighting the use of subclavian and femoral catheters to maintain effective hemodialysis.

Case Presentation: A 62-year-old female with a six-year history of end-stage renal disease (ESRD) secondary to diabetic nephropathy presented with malfunction of a right cuffed subclavian hemodialysis catheter. She had long-standing type 2 diabetes mellitus and hypertension and was on regular maintenance dialysis. Due to inadequate vessel size, she was not a candidate for arteriovenous fistula creation, necessitating catheter-based access. On September 5, 2025, the subclavian catheter became obstructed; urokinase was administered, temporarily restoring patency. However, recurrent thrombosis developed within days, leading to the insertion of a femoral catheter, which subsequently functioned well and allowed effective dialysis without further complications.

Conclusion: This case highlights the nursing management of an ESRD patient with contraindications to AV fistula creation who required subclavian and femoral catheters for hemodialysis. Recurrent thrombotic occlusions despite urokinase therapy emphasize the need for vigilant nursing assessment, evidence-based catheter care, and individualized vascular access planning to ensure safe and effective dialysis outcomes.

Article History:

Submitted: 8 October 2025

Revised: 13 January 2026

Accepted: 11 February 2026

Published: 1 March 2026

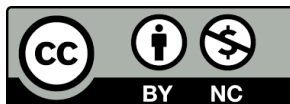
DOI: 10.31436/ijcs.v9i1.516

Corresponding author:

Patimah Abdul Wahab
Department of Medical Surgical
Nursing,
Kulliyah of Nursing,
International Islamic
University Malaysia,
Pahang, Malaysia
E-mail: patimah@iium.edu.my

This is an open-access article distributed under the terms of the Creative Commons Attribution-NonCommercial 4.0 International License (CC BY-NC 4.0), which permits non-commercial use, distribution, and reproduction in any medium, provided the original work is properly cited.

See:
<https://creativecommons.org/licenses/by-nc/4.0/>



Keywords: Arteriovenous fistula; Renal dialysis; Kidney failure, Chronic; Central venous catheters; Femoral vein; Nursing care

INTRODUCTION

An arteriovenous (AV) fistula is the most appropriate and commonest method of accessing blood vessels for long-term hemodialysis in patients with end-stage renal disease (ESRD), due to its improved patency and lower complication rates compared to central venous catheters (1,2). The Kidney Disease Outcomes Quality Initiative (KDOQI) guidelines suggest prioritizing AV fistulas when possible and reserving central venous catheters for patients with contraindications or for temporary access purpose (3,4). However, studies have reported that 20–30% of ESRD patients are not suitable candidates for AV fistula creation because of inadequate vascular anatomy, serious comorbidities, or central venous obstruction that prevents the creation of an arteriovenous fistula (5,6). According to KDOQI guidelines, the internal jugular vein is the preferred site for tunneled hemodialysis catheter placement, while subclavian access should be avoided whenever possible due to the risk of central venous stenosis (7,8). In selected patients in whom upper-body venous access, including internal and external jugular veins, is not feasible or has been exhausted, alternative catheter-based access such as femoral catheterization may be required as a last resort. Beyond the technical aspects of vascular access, nursing management is critical in ensuring catheter safety, functionality, and longevity (9).

Effective nursing interventions can reduce the risk of thrombosis, improve dialysis adequacy, and support decision-making when access revisions are required (10). There is a paucity of reports concerning ESRD patients necessitating femoral catheterization due to recurrent dysfunction of a subclavian catheter, especially in cases where obstruction persists despite thrombolytic therapy (11,12). This report discusses a patient with end-stage renal disease (ESRD) who had contraindications to arteriovenous (AV) fistula placement and experienced multiple thrombotic occlusions of a subclavian catheter, necessitating femoral catheterization for effective hemodialysis (13,14). This case highlights the importance of individualized vascular access planning and the ongoing need to evaluate alternative strategies for patients who are not candidates for AV fistula creation. This case is notable for its documentation of recurrent thrombosis in a subclavian catheter that was resistant to thrombolytic therapy in a patient with end-stage renal disease, ultimately necessitating

the use of a femoral catheter for long-term access. Reports on this progression are limited, focusing on the nursing management perspective.

CASE DESCRIPTION

A 62-year-old woman with a six-year history of end-stage renal disease (ESRD) secondary to diabetic nephropathy presented with acute malfunction of her right cuffed subclavian hemodialysis catheter. She also had long-standing type 2 diabetes mellitus, hypertension, and chronic anemia, but no history of thromboembolism. Due to inadequate vessel size, the patient was on routine maintenance hemodialysis and had previously been deemed unsuitable for arteriovenous fistula creation. On September 5, 2025, she was unable to complete her scheduled dialysis session because of a catheter blockage. Clinical assessment revealed that she was afebrile, hemodynamically stable, and showed no local or systemic signs of infection. Laboratory investigations indicated anemia (hemoglobin 82 g/L), markedly elevated urea and creatinine levels, and mild hyperkalemia (5.6 mmol/L) secondary to missed dialysis. Intracatheter urokinase was administered as a thrombolytic catheter lock at a dose of 5,000 IU per lumen, diluted in 2 mL of normal saline and allowed to dwell for 30 minutes, temporarily restoring catheter function and allowing two subsequent dialysis sessions. However, recurrent catheter-related thrombosis was confirmed based on repeated episodes of poor blood flow and inability to aspirate from the catheter lumen, despite the absence of mechanical obstruction on imaging and failure of saline flushing, findings that helped exclude fibrin sheath formation. Consequently, a femoral catheter was inserted on September 11, enabling effective dialysis. The patient remained clinically stable, with resolution of hyperkalemia and fluid overload, and was discharged with plans for continued outpatient follow-up and long-term vascular access evaluation.

Medical History

The patient is a 62-year-old woman diagnosed with end-stage renal disease (ESRD) six years ago, secondary to diabetic nephropathy. Her comorbidities include a 10-year history of type 2 diabetes mellitus and long-standing hypertension, both of which contributed to the progression of her renal disease. She also suffers from chronic anemia associated with

ESRD. However, there is no known history of thromboembolic disorders, ischemic heart disease, cerebrovascular accidents, or any other major cardiovascular conditions. Her general health status has remained stable apart from the complications related to kidney failure. The patient has not undergone renal transplantation or peritoneal dialysis at any point. She denies any known drug allergies. Her long-term medications include Amlodipine 10 mg daily, Losartan 50 mg daily, Furosemide 40 mg daily, Calcium carbonate 600 mg three times daily, Erythropoietin injections, and subcutaneous insulin for glycaemic control. These medications were continued during her current hospital stay.

Surgical History

The patient was previously evaluated for permanent vascular access. Arteriovenous (AV) fistula creation was not feasible because of inadequate vessel size, and arteriovenous graft placement was also considered but deemed unsuitable due to unfavourable vascular anatomy. The internal and external jugular veins were not selected for catheter placement because of venous stenosis and limited patency from previous catheterizations. Consequently, a right cuffed subclavian hemodialysis catheter was inserted three years ago using an ultrasound-guided, percutaneous Seldinger technique under strict aseptic conditions and local anaesthesia. A double-lumen 14 Fr catheter with a staggered tip design was used, with the catheter tip positioned at the cavoatrial junction, and correct placement was confirmed radiographically. During the current admission, the catheter developed recurrent thrombotic occlusion that was unresponsive to urokinase therapy. As a result, a temporary non-tunnelled femoral hemodialysis catheter (12 Fr) was inserted using the same ultrasound-guided Seldinger technique, with the tip positioned in the inferior vena cava, successfully restoring vascular access for effective haemodialysis.

Nursing Assessment

On admission, the patient appeared alert, cooperative, and well-oriented to time, place, and person. She reported difficulty completing her scheduled hemodialysis session due to poor catheter flow but denied chest pain, dyspnea, fever, or discomfort at the catheter site. Her general condition was stable, with vital signs indicating blood pressure of 160/78

mmHg, heart rate of 57 beats per minute, respiratory rate of 20 breaths per minute, temperature of 36.6 °C, and oxygen saturation of 97% on room air. Capillary blood glucose was 7.7 mmol/L.

Physical examination revealed pallor consistent with anemia, and mild bilateral pedal edema suggestive of fluid retention secondary to incomplete dialysis. Jugular venous pressure was mildly elevated, correlating with volume overload. Cardiovascular assessment showed a systolic murmur likely due to anemia-related increased cardiac output, with no evidence of heart failure or pulmonary congestion. Respiratory assessment found equal breath sounds bilaterally with no crackles or wheezing.

Based on these findings, the key nursing priorities included monitoring of vital signs and fluid balance, assessment of vascular access function and integrity, prevention of infection, management of anemia and electrolyte imbalance, patient education on catheter care and dietary restrictions, and provision of psychological and spiritual support.

Nursing Management

Nursing management in this case focused on maintaining vascular access patency, preventing infection, and ensuring effective hemodialysis for a patient with end-stage renal disease (ESRD) who was unsuitable for arteriovenous fistula creation. Continuous monitoring of vital signs, fluid balance, and catheter function was performed before and after each dialysis session to identify early signs of complications such as hypotension, fluid overload, or access malfunction. The subclavian and later femoral catheter sites were inspected regularly for redness, discharge, or swelling, and dressings were changed using aseptic technique to prevent infection. Laboratory parameters, including electrolytes, hemoglobin, and urea levels, were monitored to evaluate dialysis adequacy and guide ongoing care. Inspection of the right subclavian catheter site showed a clean, dry, and intact dressing with no erythema, swelling, tenderness, or discharge, suggesting the absence of local infection. Peripheral pulses were palpable and symmetrical with no signs of cyanosis or delayed capillary refill. Following the insertion of a femoral catheter, the insertion site was assessed for bleeding,

hematoma, or signs of infection and remained dry and intact throughout hospitalization.

Patient education was emphasized to enhance self-care, focusing on fluid and dietary restrictions, early reporting of infection or catheter obstruction, and adherence to treatment regimens. The nursing team also provided emotional and spiritual support to help the patient cope with anxiety and dependence on catheter-based dialysis. Collaboration with the multidisciplinary team, including nephrologists and dietitians, ensured coordinated and individualized care planning. Through vigilant assessment, evidence-based catheter care, and effective patient education, safe and adequate dialysis was achieved and maintained throughout the patient's treatment course.

DISCUSSION

This case highlights the complexities involved in nursing management of hemodialysis access for an ESRD patient who has contraindications to AV fistula creation, underscoring the necessity for individualized, evidence-based nursing care. The occurrence of recurrent thrombosis in the subclavian catheter, despite the administration of thrombolytic therapy, highlights the difficulties associated with catheter-based access in patients with multiple comorbidities. As reported in previous studies indicates that prolonged catheter use, diabetes mellitus, and vascular injury are significant risk factors for catheter dysfunction, as these conditions contribute to endothelial damage and fibrin sheath formation, thereby decreasing catheter patency (15). Furthermore, additional research indicates that thrombolytic therapy, including urokinase, may temporarily restore patency in cases where the underlying vascular pathology remains, thereby elucidating the recurrent occlusion observed in this patient (16). Furthermore, additional research indicates that thrombolytic therapy, including urokinase, may temporarily restore patency in cases where the underlying vascular pathology remains, thereby elucidating the recurrent occlusion observed in this patient (17).

Recent studies indicate that, despite conventional thinking regarding the higher infection risk related to femoral catheters, the implementation of strict aseptic nursing techniques, daily site assessments, and consistent monitoring can significantly lower infection and malfunction rates (9). The

findings align with this case, demonstrating that continuous nursing observation and strict adherence to sterile procedures effectively prevented infection and maintained stable dialysis. Additional research indicates that effective nursing management, prompt identification of catheter dysfunction, and organized patient education enhance vascular access outcomes and the adequacy of dialysis (9,18).

Research highlights the significance of individualized vascular access planning that considers patient comorbidities, which aids in minimizing complications and enhancing hemodialysis outcomes (19,20). The outcome in this case highlights the necessity of proactive, evidence-based nursing management that emphasizes infection prevention, catheter surveillance, and patient-centered care to ensure the safety, functionality, and long-term success of catheter-based hemodialysis access in ESRD patients with AV fistula contraindications.

CONCLUSION

This case highlights the significance of nursing management in ensuring effective hemodialysis access for patients with end-stage renal disease who are unable to have arteriovenous fistula creation. The study highlights the importance of research-based nursing care, focusing on continuous monitoring of catheter function, early identification of complications, and thorough patient education regarding access maintenance and dietary compliance. Effective nursing management is essential to maintaining dialysis adequacy, enhancing patient safety, and facilitating continuity of care in complex cases of end-stage renal disease (ESRD).

CONFLICT OF INTEREST

The authors have no conflicts of interest to disclose.

FUNDING

This research received no specific grant from any funding agency in the public, commercial, or not-for-profit sectors.

ACKNOWLEDGEMENTS

The authors express gratitude to the nursing staff and dialysis team at our teaching hospital for their commitment to patient care and

support. Gratitude is expressed to the Faculty of Nursing, International Islamic University Malaysia, for their academic guidance and supervision during the preparation of this case report.

AUTHOR CONTRIBUTIONS

MMA: Contributed to the conceptualization and design of the case report, conducted data collection and clinical documentation of nursing management, and prepared the initial draft of the manuscript. MMA was also involved in organizing the clinical findings and integrating relevant literature into the discussion.

PAW: Provided overall supervision and academic guidance throughout the preparation of the manuscript, contributed to critical review and substantive revision of the content, and refined the manuscript for intellectual clarity and coherence.

REFERENCES

- Karakaya E, Akdur A, Beyazpinar Ds, Kavasoglu L, Kahraman G, Şirinoğlu T. Comparison of use of central venous catheter and arteriovenous fistula as initial vascular access in 735 patients with end-stage renal disease. *Turkish J Clin Lab.* 2022;13(1):124–9.
- Lok CE, Huber TS, Orchanian-Cheff A, Rajan DK. Arteriovenous Access for Hemodialysis: A Review. *Jama.* 2024;331(15):1307–17.
- Plimon M, Leinweber ME, Hofmann AG, Ksiazek SH, Taher F, Werzowa J, et al. Prevalence and Center Variability of Catheter-Based Hemodialysis in Vienna: Insights from the Vienna ACTS NOW Study. *J Clin Med.* 2024 Nov 1;13(22).
- Venegas-Ramírez J, Hernández-Fuentes GA, Palomares CS, Diaz-Martinez J, Navarro-Cuellar JI, Calvo-Soto P, et al. Vascular Access Type and Survival Outcomes in Hemodialysis Patients: A Seven-Year Cohort Study. *Med.* 2025 Apr 1;61(4).
- Zhang F, Li J, Yu J, Jiang Y, Xiao H, Yang Y, et al. Risk factors for arteriovenous fistula dysfunction in hemodialysis patients: a retrospective study. *Sci Rep.* 2023 Dec 1;13(1).
- Kaloo S, Blake PG, Wish J. A Patient-Centered Approach to Hemodialysis Vascular Access in the Era of Fistula First. *Semin Dial.* 2016;29(2):148–57.
- Aitken E, Anijeet H, Ashby D, Barrow W, Calder F, Dowds B, et al. UK Kidney Association Clinical Practice Guideline on vascular access for haemodialysis. Vol. 26, *BMC Nephrology.* 2025.
- Schröppel B, Bettac L, Schulte-Kemna L, Kächele M. Placement of tunnelled haemodialysis catheters—interventional standard. *Nephrol Dial Transplant.* 2025;40(2):264–72.
- Evalarozza CL, Baleña SB. Guarding the Line: A Systematic Review of Nurse-Led Infection Prevention Protocols for Reducing Catheter-Related Bloodstream Infections in Hemodialysis Settings. *Int J Multidiscip Res.* 2025;7(4):1–34.
- Silva BSM, Dos Santos LM, Rocha PK, Mota ANB, Avelar AFM, Kusahara DM. National practice of Nursing professionals in the insertion of peripheral vascular access devices. *Rev Lat Am Enfermagem.* 2024;32.
- Buchanan C, Burt A, Moureau N, Murray D, Nizum N. Registered Nurses’ Association of Ontario (RNAO) best practice guideline on the assessment and management of vascular access devices. Vol. 25, *Journal of Vascular Access.* SAGE Publications Ltd; 2024. p. 1389–402.
- Casanova-Vivas S, Ballestar-Tarín ML, García-Molina P, Lorente-Pomar AB, Palau Gomar A, Hevilla Cucarella EB, et al. An Explanatory Model of Vascular Access Care Quality: Results of a Cross-Sectional Observational Study. *Nurs Reports.* 2024 Jun 1;14(2):1049–57.
- Kakareko K, Kwiatkowska K, Rydzewska-Rosolowska A, Glowinska I, Hryszko T. Fluoroscopy-free insertion of tunneled hemodialysis catheters: ensuring safety and precision – a retrospective observational study. *BMC Nephrol.* 2025;26(1).
- De Oliveira Harduin L, Barroso TA, Guerra JB, Filippo MG, De Almeida LC, De Castro-Santos G, et al. Guidelines on vascular access for hemodialysis from the Brazilian society of angiology and vascular surgery. *J Vasc Bras.* 2023;22.
- Mohazzab A, Khavanin Zadeh M, Dehesh P, Abdolvand N, Rahimi Z, Rahmani S. Investigation of risk factors for tunneled hemodialysis catheters dysfunction: competing risk analysis of a tertiary center data. *BMC Nephrol.* 2022 Dec 1;23(1).
- Hilleman D, Campbell J. Efficacy, safety, and cost of thrombolytic agents for the management of dysfunctional hemodialysis catheters: A systematic review. Vol. 31, *Pharmacotherapy.* 2011. p. 1031–40.

17. Khalid M, Akram Malik M, Imran M, Asif Gurmani M, Jaskani K, Khan DG. Comparison Of Internal Jugular Vein With Subclavian Vein Hemodialysis Catheter Access. Vol. 8, JUMDC.
18. Sethi J, Gaur M, Rathi M, Kohli H. Tunneled femoral vein catheterization for long-term hemodialysis - Experience from a tertiary care center. *Indian J Nephrol*. 2022 Jul 1;32(4):371–4.
19. Murea M, Woo K. New Frontiers in Vascular Access Practice: From Standardized to Patient-tailored Care and Shared Decision Making. *Kidney360* [Internet]. 2021 Aug 1 [cited 2025 Oct 5];2(8):1380–9. Available from: https://journals.lww.com/kidney360/fulltext/2021/08000/new_frontiers_in_vascular_access_practice__from.19.aspx
20. Sun J, Liu Y, Chen J, Zhou Y, Fan H, Zhao Q. Catheter replacement combined with antiplatelet therapy in hemodialysis catheter-related right atrial thrombus: a potential treatment approach. *BMC Cardiovasc Disord*. 2025 Dec 1;25(1).