

## MULTI-FREQUENCY ULTRASOUND IMAGING: PHANTOM STUDY

SITI NUR MASTURAH BINTI ABDUL MALEK

DEPARTMENT OF DIAGNOSTIC IMAGING AND RADIOTHERAPY, KULLIYAH OF ALLIED HEALTH SCIENCES, INTERNATIONAL ISLAMIC UNIVERSITY MALAYSIA, JLN SULTAN AHMAD SHAH, 25200 KUANTAN, PAHANG, MALAYSIA.

[sitinurmasturah777@gmail.com](mailto:sitinurmasturah777@gmail.com)

SAYED INAYATULLAH SHAH (CORRESPONDING AUTHOR)

DEPARTMENT OF DIAGNOSTIC IMAGING AND RADIOTHERAPY, KULLIYAH OF ALLIED HEALTH SCIENCES, INTERNATIONAL ISLAMIC UNIVERSITY MALAYSIA, JLN SULTAN AHMAD SHAH, 25200 KUANTAN, PAHANG, MALAYSIA.

[inayatullah@iium.edu.my](mailto:inayatullah@iium.edu.my)

### ABSTRACT

**Introduction:** In ultrasound imaging there is compromise between the penetration of signal at certain depths into the object and image resolution as the ultrasound probe only can transmit single frequency signals in one transmission. Using curvilinear ultrasound probe with 2 to 5 MHz frequency bandwidth, this study investigated the use of multi-frequency imaging to enhance the quality of phantom images.

**Methods:** Siemen Acuson X150 with curvilinear ultrasound transducer was used to scan the organs of interest (kidney, gallbladder and pancreas) of the ultrasound abdominal phantom. Different images at the different selected frequencies (2.5, 3.6 and 5.0 MHz) were created by fixing the position and the orientation of the transducer in each of the scanning process. Different-frequency images were generated and combined to produce composite (multi-frequency) image. **Results:** In this study, the quality of the composite image was evaluated based on signal-to noise ratio (SNR) and the obtained results were compared with the single frequency images. Besides, the comparison was also made in terms of overall image quality (noise and sharpness of organ outline) through perceived image quality analysis. Based on calculated SNR, the composite image of the kidney, gallbladder and pancreas recorded higher SNR value as compared to the single frequency images. However, through perceived image quality, most of the observers viewed that the quality of the composite image of the kidney, gallbladder and pancreas is poor as compared to the single frequency image. **Conclusions:** Image quality of ultrasound imaging is improved by combining multiple ultrasound frequency images into a single composite image. This is achieved as high SNR is obtained in the composite image. However, through perceived image quality, the overall image quality of the composite image was poor.

**KEYWORDS:** Ultrasound Imaging, Multiple Frequency, Signal-to-Noise Ratio

### INTRODUCTION

Ultrasound has been widely used for a number of clinical examinations as the equipment is portable, obtainable as well as lower in cost as compared to other imaging modalities. However, ultrasound imaging has a problem of penetration of signals at certain depths into the medium and image resolution, since the ultrasound transducer can only transmit single frequency signal in one transmission. The generation of high resolution image can be achieved by using higher frequency signal. However, the capability of these ultrasound signals to reach the deeper structure decreases. This

is because higher ultrasound signals are more attenuated in the tissue as compared to low frequency signals. Hence, these ultrasound signals can be only applied to image the superficial structures. In contrast, lower frequency signals are used in imaging the deeper structure. However, the image quality produced by these ultrasound signals is inferior.

Various imaging techniques have been developed to overcome this limitation. These imaging techniques include tissue harmonic imaging (THI) and compound imaging. In tissue harmonic imaging, the generation of the ultrasound image is based on high-frequency harmonic signal which essentially is the doubling of transmitted signals. Meanwhile, compound imaging referred as the technique whereby multiple images from different steering angles or different frequencies are combined to form a single, multi-angle or multi-frequency compound image.

Yoshizumi et al. (2009) proved that multi-frequency ultrasound imaging is capable to improve the quality of the ultrasound image in which higher SNR value was recorded by the superimposed image as compared to single frequency images. This is supported by Varray et al. (2012). According to Varray et al. (2012), both the SNR and the image resolution is enhanced by the application of multi-frequency imaging. As different frequency images are combined to form a single composite image, the appearance of each speckle noise is averaged, resulting in improved image quality. The appearance of speckle noise could degrade the quality of the ultrasound image causing the difficulty in the visual observation. Besides, the presence of speckle noise also could interrupt the detection of very small pathology such as small tumor. Thus, it is necessary to reduce the appearance of speckle noise in the ultrasound image so that more accurate diagnosis can be made by the radiologist. The capability of multi-frequency imaging in improving the quality of ultrasound image had also manifested in intravascular ultrasound (IVUS) imaging. Teng et al. (2015) demonstrated that, combination of two different frequency images provided more comprehensive visualization of the human cadaver coronary artery. Furthermore, recent literature suggests the development of multi-frequency ultrasound imaging technique for improvement of the quality of ultrasound images (Sayed 2018).

This work investigates the effects on image quality of multi-frequency ultrasound images obtained by scanning abdominal phantom using curvilinear ultrasound probe with different transmitted frequency signals (2.5, 3.6 and 5.0 MHz).

## METHODS

### Equipment and materials

Siemen Acuson X150 ultrasound machine which equipped with two types of transducers; linear array transducer (VF10-5 transducer) and curved array transducer (CH5-2 transducer) were used. The ultrasound abdominal phantom that was scanned in this study is from Kyoto Kagaku. This phantom was chosen as it consists of various organs including the ribs, lungs, stomach, spleen, liver, gallbladder, kidneys, pancreas, abdominal aorta and inferior vena cava. The size of this phantom is approximately 52x18x28 cm and 12 kg in weight.

To process and analyze images, two imaging software were employed. These imaging softwares are iMagic ultrasound image management software and ImageJ software. iMagic software was used in obtaining the ultrasound image from the ultrasound machine interfaced through a video cable. Whereas, ImageJ software was utilized to process images in which different frequency ultrasound images were combined to form a single multi-frequency (composite) image. ImageJ software was also used in this study to analyze the quality of each of the ultrasound images.

### Scanning of organ phantom

The abdominal organs of interest in this study were kidney, gallbladder and pancreas. Curvilinear ultrasound probe with 2.5, 3.6 and 5.0 MHz frequency signals was used to scan each of these organs. Before the scanning begins, the acoustic gel was spread on the transducer face to maximize the conduction of ultrasonic sound waves into and from the patient. The scanning began with 2.5 MHz frequency signal and followed with 3.6 MHz and 5.0 MHz frequency signal. The orientation and the position of the transducer were kept constant in every scanning process. All the scanned images were saved in Portable Network Graphics (PNG) format. The scanning process was repeated to scan all the organs of interest.

By using ImageJ software, different frequency images (2.5, 3.0 and 5.0 MHz) were combined into a single composite image. No image filter was applied to each of the image. The quality of each of the scanned images was evaluated by calculating the SNR value.

$$\text{SNR} = \mu / \sigma$$

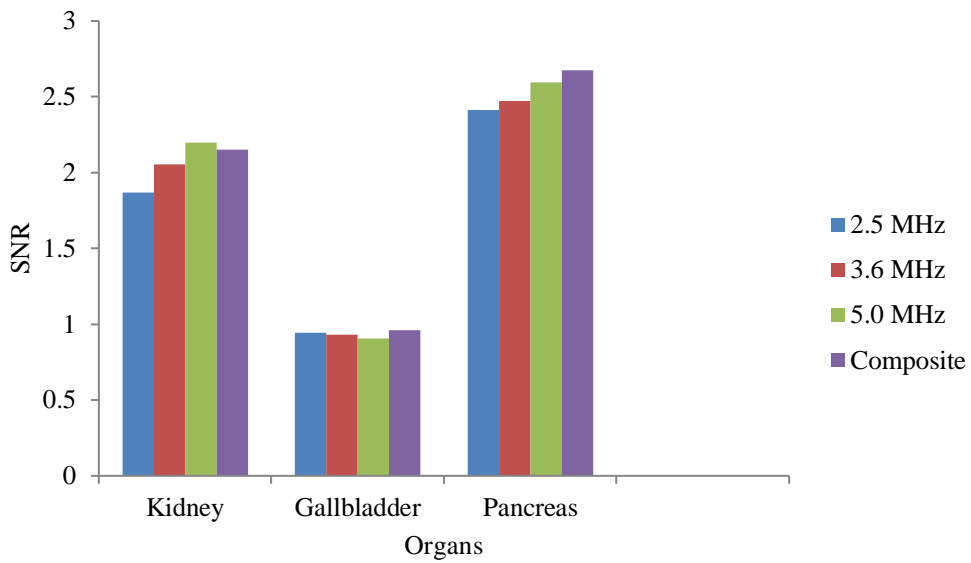
where  $\mu$  is the value of mean and  $\sigma$  is the value of standard deviation of the region of interest (ROI). The SNR of each of the single frequency images was compared with the multi-frequency (composite) image. Besides, the comparison on overall image quality between the multi-frequency image and the single frequency images was also performed which was conducted through perceived image quality by thirteen (13) final year students and two radiographers. Evaluation on the overall image quality was based on the noise and sharpness of the organ outline.

## RESULTS

### SNR of single frequency images and multi-frequency images

Figure 1 illustrates the SNR of single frequency images and composite image of the organs of interest. For the kidney, the highest SNR value which is 2.197 was recorded by using 5.0 MHz frequency. This followed by 3.6 MHz frequency signal which recorded 2.055. By using 2.5 MHz frequency, the lowest SNR value was recorded, 1.870. In contrast with the kidney, for gallbladder, the highest SNR value which is 0.942 was recorded by using 2.5 MHz frequency. Meanwhile, with the use of 3.6 MHz frequency signal, 0.931 SNR was obtained. Lowest SNR value which is 0.906 was recorded when 5.0 MHz frequency signal was applied. For pancreas, the highest SNR value which is 2.595 was recorded by using 5.0 MHz frequency signal and this followed by 3.6 MHz frequency signal which recorded 2.474. It can be seen clearly that the lowest value of SNR was recorded by 2.5 MHz frequency signal which is 2.415.

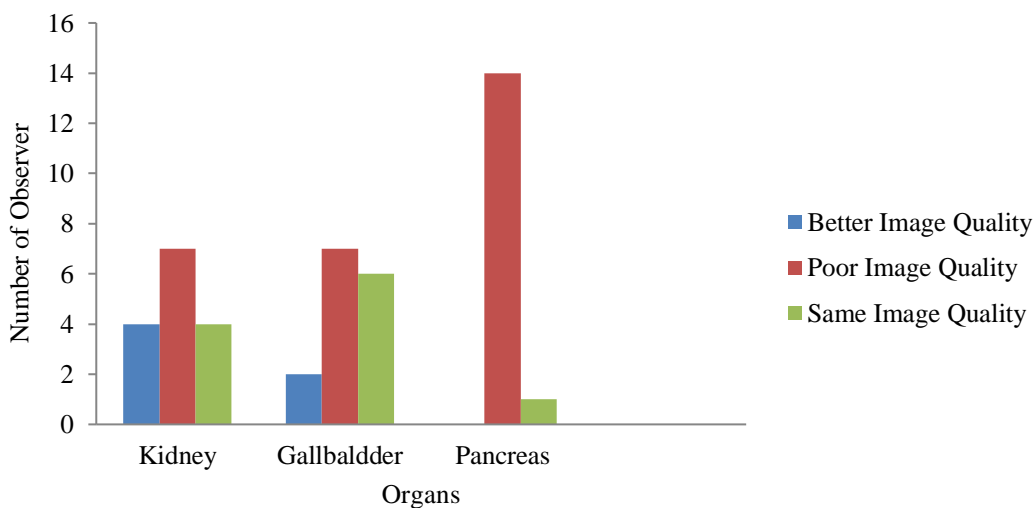
In comparing the SNR value of the single frequency images and multi-frequency image, the multi-frequency image of the kidney recorded higher SNR value which is 2.152 as compared to 2.5 MHz (1.870) and 3.6 MHz (2.055). However, the recorded SNR is slightly lower as compared to 5.0 MHz frequency signal. For the gallbladder, the multi-frequency image higher SNR value was recorded, which is 0.961 as compared to single frequency images which are 0.942 (2.5 MHz), 0.931 (3.6 MHz) and 0.906 (5.0 MHz). Besides, in the case of pancreas multi-frequency image, record greater SNR value which is 2.675 as compared to single frequency images, 2.415 (2.5 MHz), 2.474 (3.6 MHz) and 2.595 (5.0 MHz) was recorded.



**Figure 1.** SNR of single frequency images and composite image of the organs of interest.

**Overall image quality of multi-frequency image as compared to single frequency images**

Figure 2 illustrates the overall image quality of the multi-frequency image as compared to single frequency images in which this comparison was performed through perceived image quality by 13 final year students and two radiographers from Diagnostic Imaging and Radiotherapy Department. For the kidney, most of the observers responded that the overall image quality of the kidney multi-frequency image is poor as compared to the single frequency images. Only four of the observers noted that the quality of the multi-frequency image is improved as compared to the single frequency images.



**Figure 2.** Overall image quality of composite image as compared to single frequency images based on perceived image quality.

For the gallbladder, seven of the respondents observed that the overall image quality of the multi-frequency gallbladder image is poor as compared to the single frequency images. Meanwhile, six

of the respondents found that there is no improvement in the quality of the multi-frequency gallbladder image as compared to single frequency images. Only two of the respondents observed that the quality of the gallbladder multi-frequency image is improved as compared to the single frequency images.

For pancreas, most of the observers noted that the overall quality of the pancreas multi-frequency image is poor as compared to single frequency images. Only one observer claimed that the overall image quality of the pancreas multi-frequency image is just the same as the single frequency images.

## DISCUSSION

In this study, the quantification of the noise was performed by calculating the SNR value of the ultrasound image. Based on the results obtained, the value of SNR increased as the frequency of the ultrasound signal was increased. The highest SNR value was recorded by using higher frequency signal (5.0 MHz) in both kidney and pancreas ultrasound images. In contrast, the SNR value of the gallbladder ultrasound image decreased as the frequency was increased. Speckle noise is the most which contribute the noise in the ultrasound image. Speckle noise can be referred to the granular appearance of the ultrasound image which results from constructive and destructive interference of numerous scattered echoes. In ultrasound imaging, scattering happens when the ultrasound beam encounters the reflectors when physical dimensions are approximately equal or smaller than the ultrasound wavelength. For both kidney and pancreas image, it can be suggested that less speckle noise was produced as higher frequency signal was applied. This is due to less scattering interaction occurred between the sound waves and the tissue as the wavelength of higher frequency signal is short. Thus, less scattering resulted less speckle noise.

In comparing the value of SNR between the composite image and the single frequency images, the composite image recorded higher SNR value as compared to single frequency images. Higher SNR values were recorded in the composite images of gallbladder (0.961) and pancreas (2.675) as compared to their single frequency images. Different frequency signals generate different speckle noise pattern. According Entrekina, Porter, Sillesen, Wong, Cooperberg and Fix (2001); Huber, Wagner, Medl and Czembirek (2002); and Mesurolle et al. (2007), as multiple frequency images were combined to form a single composite image, the appearance of each speckle patterns averaged, and this results in improved image quality. The obtained results are in line with the previous study by Yoshizumi et al. (2009) and Varray et al. (2012) in which high SNR was obtained in the multi-frequency image.

Although, higher SNR was obtained in the composite image, but through perceived image quality, most of the respondent observed that the quality of the composite image is poor as compared to the single frequency images. This result could be influenced by the respondent in which most of the respondent does not have the specialty to evaluate the ultrasound image. According to Martin (2007), observer's visual threshold may limit the perceived image quality in which this could be overcome if the observer is trained to view a lot of images. Besides, it is utmost important for the observer to require a set of imaging criteria to enable the decision regarding the quality of the image. Thus, proper imaging criteria must be provided so that the evaluation on the quality of the composite image can be done appropriately.

## CONCLUSION(S)

It is concluded that the image quality of the ultrasound imaging may be improved by combining different ultrasound frequency images into a single composite image. This was achieved as high SNR values were obtained by analyzing multi-frequency (composite) images that proved the reduction in

speckle noise in the image. In contrary, perceived image quality investigations show that the overall image quality of the multi-frequency image is poor. However, further investigations require for extracting the valuable information from the multi-frequency ultrasound images, which may be translated to diagnostic ultrasound imaging.

#### ACKNOWLEDGEMENT(S)

The authors would like to acknowledge the Department of Diagnostic Imaging and Radiotherapy, International Islamic University Malaysia (IIUM) for providing the facilities and equipment to carry out the study. This research is supported by the International Islamic University Malaysia under the Research Initiative Grant Scheme, RIGS #16-302-0466.

#### REFERENCES

- Entrekin, R.R., Porter, B.A., Sillesen, H.H., Wong, A.D., Cooperberg, P.L., & Fix, C.H. (2001). Real-time spatial compound imaging: application to breast, vascular, and musculoskeletal ultrasound. *Semin Ultrasound CT MR*, 22(1), 50-64.
- Huber, S., Wagner, M., Medl, M., & Czembirek, H. (2002). Real-time spatial compound imaging in breast ultrasound. *Ultrasound Med Bio*, 28(2), 155-163.
- Martin, C. J. (2007). The importance of radiation quality for optimisation in radiology. *Biomed Imaging Interv J*, 3.2e38; doi: [10.2349/bij.3.2.e38](https://doi.org/10.2349/bij.3.2.e38)
- Mesurole, B., Bining, H.J., El Khoury, M., Barhdadi, A., & Kao, E. (2006). Contribution of tissue harmonic imaging and frequency compound imaging in interventional breast sonography. *J Ultrasound Med*, 25(1), 845-855.
- Teng, M., Mingyue, Y., Zeyu, C., Chunlong, F., Kirk, S., & Qifa, Z. (2015). Multi-frequency Intravascular Ultrasound (IVUS) Imaging. *Transaction on Ultrasonics, Ferroelectrics, and Frequency Control*, 62(1), 97-107.
- Sayed, I.S. (2018). Allah's Wondrous Creatures, the Holy Qur'an and Technological Inventions: Ultrasound Imaging. *The International medical Journal Malaysia*, Vol. 17 Special Issue 1, 83-88.
- Varray, F., Cachard, C., Kybic, J., Novell, A., Bouakaz, A., & Basset, O. (2012). A Multi-frequency Approach to Increase the Native Resolution of Ultrasound Images. *European Signal Processing Conference*, 2733-2736.
- Yoshizumi, N., Saito, S., Koyama, D., Nakamura, K., Ohya, A., & Akiyama, I. (2009). Multiple-frequency ultrasonic imaging by transmitting pulsed waves of two frequencies. *The Japan Society of Ultrasonic in Medicine*, 36, 53-60.